



Scholars Research Library

Der Pharmacia Lettre, 2009, 1 (2) 182-192
(<http://scholarsresearchlibrary.com/archive.html>)



Infectious Mononucleosis : A Review

Nachiket S Dighe¹, Shashikant R Pattan¹, Sanjay B Bhawar², Vinayak M Gaware¹,
Mangesh B Hole¹, Priyanka P Gadhave¹ and Santosh B Dighe²

¹Department of Medicinal Chemistry, Pravara Rural College of Pharmacy, Pravaranagar, India

²Department of Pharmacology, Pravara Rural College of Pharmacy, Pravaranagar, M.S, India

Abstract

Infectious mononucleosis is an infectious, very widespread viral disease caused by the Epstein-Barr virus(EBV), a type of Herpes virus. It is most common among adolescents and young adults and is characterized by fever, sore throat and fatigue, along with several other possible signs and symptoms. Primary infections with EBV in childhood either remain silent or are accompanied merely by mild signs and symptoms in the throat and respiratory tract, whereas the highest rate of infectious disease occurs in older children and young adults, especially college students where the transmission of virus takes place through saliva during unprotected sexual acts. EBV infects the epithelium of the oropharynx and salivary glands. Potential mortal complications include splenic rupture, bacterial superinfections, hepatic failure and the development of viral myocarditis. Meningitis, encephalitis, hemiplegia and transverse myelitis may take place. Diagnostic criterion is the presence of 50% lymphocytes with at least 10% atypical lymphocytes (large, irregular nuclei), while the person also has fever, pharyngitis and adenopathy. Diagnosis is to be confirmed by a serological test. The antiviral drug valacyclovir has recently been shown to lower or eliminate the presence of the EBV in subjects afflicted with acute mononucleosis.

Keywords: Infectious mononucleosis, Epstein-Barr virus, Pfeiffer's disease.

Introduction

Infectious mononucleosis (also known as EBV infectious mononucleosis or Pfeiffer's disease or Filatov's disease[1]and colloquially as kissing disease from its oral distribution or as mono in North America and as glandular fever in other English-speaking countries) is an infectious, very widespread viral disease caused by the Epstein-Barr virus, a type of Herpes virus, which well over 90% of all adults are exposed to at some point in their life.[2] Most people are exposed to

the virus as children, when the disease produces no noticeable symptoms or only flu-like symptoms. In underdeveloped countries, people are exposed to the virus in early childhood more often than in developed countries, which is why the disease in its observable form is more common in developed countries. It is most common among adolescents and young adults.[3] Especially in adolescents and young adults, the disease is characterized by fever, sore throat and fatigue, along with several other possible signs and symptoms. It is primarily diagnosed by observation of symptoms, but suspicion can be confirmed by several diagnostic tests. The syndrome was described as an infectious process by Nil Filatov in 1887 and independently by Emil Pfeiffer in 1889.[4]

History [5, 6]:

Table I : History of Infectious mononucleosis

1889	Evidence of hepatic dysfunction in infectious mononucleosis in adults has been well established. Pfeiffer, 1 in his original description of glandular fever in 1889, mentioned enlargement of the liver as one of the major physical findings in the disease
1920	In 1920, mono first got its name. Researcher Sprunt and his associates gave the name infectious mononucleosis to cases that showed acute leukemia that seemed to resolve on its own with blast like cells in the blood.
1964	VIRUS - The virus that is responsible for infectious mononucleosis. Discovered in 1964, this virus. (B-cells). A mono spot test (positive for infectious mononucleosis) Epstein -Barr virus antigen
1984	However, it would be misleading to suggest that people with infectious mononucleosis are at increased risk for cancer. In fact, there is evidence suggesting infectious mononucleosis develops as part of the body's healthy and normal reaction to the Epstein-Barr virus
1985	An 18-year-old student had a similarly unexplained two-year history of fevers, joint pains and rashes that caused her to miss nine months of school .. Researchers now studying the problem report that in many cases the syndrome first appears after an attack of infectious mononucleosis
1987	Her doctor told her she had infectious mononucleosis, a common infection caused by a common virus - the Epstein-Barr virus
2000	Infectious mononucleosis was the diagnosis. The Epstein-Barr virus causes infectious mononucleosis. The virus can live in the mouth and saliva of people long after all signs of illness
2001	Review of the clinical manifestations, laboratory findings and complications of infectious mononucleosis. The patient reported no relevant history except for an evaluation 4 days earlier for exudative pharyngitis and cold like symptoms, when a diagnosis of streptococcal infection.
2003	New research confirms a long-suspected link between infectious mononucleosis also known as the "Kissing disease" and a cancer commonly found in young adults. Studies have shown that there is a higher rate of the cancer in people with a history of mononucleosis
2006	Why some patients recover quickly from symptomatic infectious mononucleosis and others develop a prolonged and disabling illness has .. Explain to patients that most people recover quickly from infectious mononucleosis, but some have prolonged symptoms.

Epidemiology

Infection by EBV is more common in developing countries where sanitation, hygiene and cooking are not as sterile as in nations such as the US. Pre chewed food and shared saliva lead to a much higher incidence of infection than in the US, where shared saliva is characteristic of

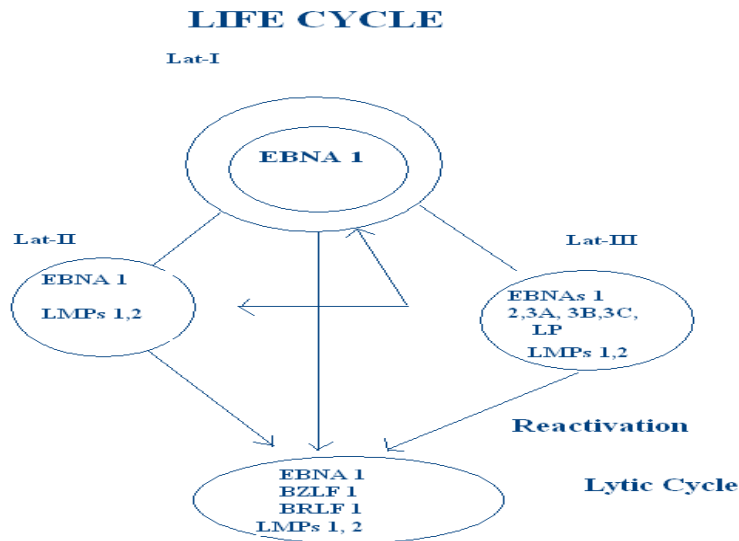
sexual activity in adolescence and early adulthood. Interestingly, the patterns of clinical pathology are reversed. Infants and young children do not usually get infectious mononucleosis but will test positive for anti EBV antibody. However, the highest rate of infectious disease occurs in older children and young adults, especially college students. [7] The reasons for this observation are not understood. "It is likely, therefore, that primary infections with EBV in childhood either remain silent or are accompanied merely by mild signs and symptoms in the throat and respiratory tract".[4]

Distribution

EBV infection is worldwide. Even remote populations such as isolated tribes in Alaska and Brazil have shown antibody reactions to EBV antigens. Infection occurs early in life in most developing countries and usually without clinical symptoms. In China, almost 80% were positive for EBV within their first year of life [8]. Compare this to studies at Yale, where almost 50% of students were susceptible when they entered college at an average age of eighteen years old. Mono is mainly a disease of college students, white collar workers and military personnel, who are able to avoid infection until adult life because of socioeconomic status. EBV does not discriminate between the sexes or among racial groups. [9]

Life Cycle

Figure I: Life Cycle of Epstein-Barr virus

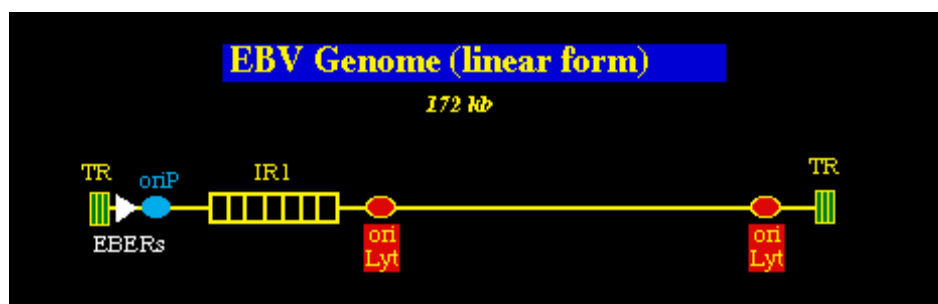


The major antigens of EBV include six EBV-associated nuclear antigens (EBNA, 1,2,3a,3b,3c,- leader protein (LP)), early antigen (EA), which comes in diffuse (D) and restricted (R) forms, viral capsid antigen (VCA), EBV-induced membrane antigen (MA) and latent membrane proteins (LMP) [10]. The six EBNA proteins constitute a family of EBV-associated nuclear antigens. EBNA-1 is important for maintenance of the plasmid viral DNA in latently infected cells and in activation of viral DNA replication. EBNA-1 is a 60 to 85-kDa polypeptide which contains a variable number of glycine-alanine repeats. EBNA-1 is expressed in all EBV infected cells, but the other EBNAs are not. In type-1 latency, EBNA-1 alone is expressed, which occurs in Burkitt's lymphoma. In type-2 latency, LMP is also expressed. This state is characteristic of

NPC and EBV-positive Hodgkin's lymphomas. EBNA-2, with a molecular weight of 81 to 95-kDa, is essential for the immortalization of lymphocytes by EBV. It is the first gene expressed, in conjunction with EBNA-LP and serves as a master switch in those cellular and viral genes involved in transformation. EBNA 3A (136kD), 3B (142kD) and 3C (147kD) are involved in EBV transformation of primary human B lymphocytes. LMP1 interacts with tumor necrosis factor receptor-associated factor 1 to affect cell growth and death signaling pathways. It immortalizes B cells by activating the apoptosis-antagonizing *bcl-2* gene [11]. Early antigen (EA) appears before viral replication. The diffuse component is found in the nucleus while the restricted component is in the cytoplasm. Viral capsid antigen (VCA) appears after viral replication and constitutes the virion. It is found in both the cytoplasm and the DNA (1). EBV-induced membrane proteins (MA) include those of molecular weights 340-350kDa (gp350), 220kDa (gp220), 110kDa (gp110) and 85kDa (gp85). gp350/220 binds to CD21 facilitating entry into the B lymphocyte by receptor-mediated endocytosis. gp85 is homologous to the herpes simplex viral protein and is important in fusion of the virus to the cell membrane. gp85 also causes virus neutralization in the presence of complement. gp 110 resides mainly in the nuclear membranes and endoplasmic reticulum of infected cells. Recent evidence of its participation in the ADCC reaction indicates its expression on the cell surface as well. gp350 and gp85 can be targeted by virus-neutralizing antibodies. gp350 evokes ADCC and T-cell mediated responses and inhibits viral release from the cell. It is the most studied of the viral antigens in attempts for vaccine development [12].

Structure [13]

Figure II: Genomic structure of Epstein-Barr virus



EBV was the first herpesvirus to be completely sequenced, in 1984. It is 172 kbp in size and contains a single long unique region that is interspersed with a number of internal repeats and flanked by terminal direct repeats at either end. The largest of the internal repeats is known as IR1 and corresponds to repeating Glycine-Alanine motif that is part of the EBNA1 protein. Two distinct types of EBV (EBV-1 & EBV-2) have been identified, which have extensive homology and are equally common in different geographical areas and populations. The significance of these different virus types remains uncertain. EBV genome (linear form).

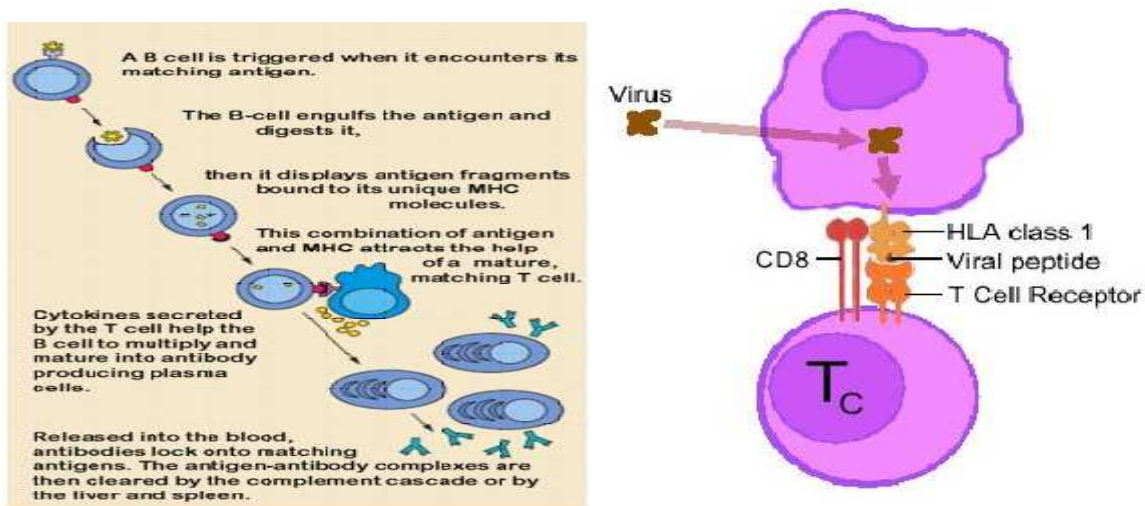
Functions of EBV Latent Genes [13]

Table II: Functions of EBV Latent Genes

Gene	Function
EBNA-1	Latent phase viral DNA replication: binds the viral latent origin, <i>oriP</i> . EBNA1 also activates transcription of other latent genes. It is minimally antigenic due to a GlyAla repeat.
EBNA-2	Transcriptional activator of viral and cellular genes: Targeted to DNA by the cellular J kappa recombination signal sequence binding protein (RBPJ) -- <i>this is analogous to HSV VP16 which also cannot bind DNA directly</i>
LMP-1	Transcriptional activator: Engages signaling proteins for the tumor necrosis factor receptor family (TRAFs), activates NF/B & mimics CD40 signals to cause B cell activation and differentiation. Prevents apoptosis by inducing <i>bcl-2</i> (and <i>NF/B</i>).
EBNA-3C	Transcriptional activator of CD21, LMP1. May allow fine control of EBNA2 (it binds RBPJ and stops it from contacting DNA)
EBNA-3A	Contributes to the initiation of cellular proliferation in EBV infected B cells -- uncertain how. Like EBNA-3C, it binds RBPJ

Pathophysiological [14]

Figure III: Pathophysiological of Epstein-Barr virus



- EBV infects the epithelium of the oropharynx and salivary glands.
- Lymphocytes in the tonsillar crypts are directly infected .
- Infected B cells and activated T cells proliferate and expand.
- Polyclonal B cells produce antibodies to host and viral protein
- Memory B cells (not epithelial cells) are reservoir for EBV.
- EBV receptor is CD21 (found on B cell surface)
- Cellular immunity (suppressor T cells, NK cells, cytotoxic T cells) more important than humoral immunity in controlling infection

Mortality/morbidity

Fatalities from mononucleosis are extremely rare in developed nations. Potential mortal complications include splenic rupture, bacterial super infections, hepatic failure and the development of viral myocarditis. Uncommon, nonfatal complications exist, including various forms of CNS and hematological affection.[15]

CNS: Meningitis, encephalitis, hemiplegia and transverse myelitis. EBV infection has also been proposed as a risk factor for the development of multiple sclerosis (MS), but this has not been affirmed.

Hematologic: EBV can cause autoimmune hemolytic anemia (direct Coombs test is positive) and various cytopenias. [16]

Incubation period 1 to 2 months [16]

Transmission

The virus is spread by person-to-person contact, via saliva (on hands or toys, or by kissing). In rare instances, the virus has been transmitted by blood transfusion. [17]

Complications [18, 19]

IM is usually a benign and self-limiting disease. Certain morbid complications may arise which account for 30 deaths per annum in the US. These complications include

CNS	CNS complications include meningitis, encephalitis and the Guillain-Barre syndrome. These complications may precede, accompany or postdate IM by several weeks. Recovery is usual. Although CNS disorders may occur as the sole manifestation of an EBV infection, most cases arise during the course of IM.
Hepatic	Almost all IM patients have deranged LFTs, overt jaundice is uncommon (5-10%) and complete recovery is the rule. More severe cases include massive hepatic cirrhosis and Reye's syndrome.
Splenic rupture	This is a very rare complication of IM and when it occurs, urgent surgery is required.
Pharyngeal and tracheal obstruction	These may occur due to massive enlargement and oedema of the tonsils and adenoids. A short course of steroids is indicated.
Immunological complications	These include haemolytic and aplastic anaemia, thrombocytopenia, hypogammaglobulinaemia, agranulocytosis and haemophagocytosis. EBV induced auto antibodies may be involved in these cases.
Chronic IM	Rarely, chronic cases of IM occur where symptoms persist for years and death may result from lymphomatous disease. In these cases, there is the persistence of the acute profile of IM, with elevated titres of IgG against VCA and EA-D antigens.

There is an absence of antibodies against EBNA 1 and a positive monospot test. High titres of virus can be isolated from throat washings.

Signs and Symptoms [20,21]

Figure IV: Signs and Symptoms of Infectious mononucleosis

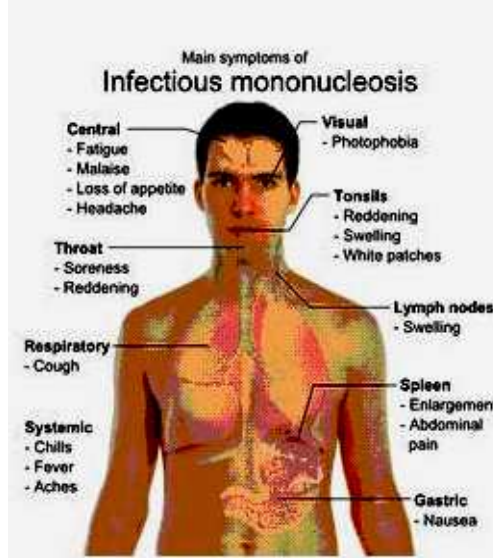


Table IV: Signs and Symptoms of Infectious mononucleosis

Organ involved	Symptoms & signs
Spleen	Splenomegaly (an enlarged spleen)
Joints	Arthritis in one or more joints
Kidneys	Glomerulonephritis
Nervous system	Meningoencephalitis Bell's palsy (facial palsy) Transverse myelitis Guillain-Barré syndrome
Gastrointestinal tract	Hepatitis
Lungs	Interstitial pneumonia
Heart	Pericarditis
Eyes	Eyelid swelling Keratitis Uveitis Conjunctivitis Retinitis
Blood system	Autoimmune haemolytic anaemia (breakdown of red cells) Thrombocytopaenia (reduced platelet count) Neutropaenia (reduced white cell count) Cold agglutinins (proteins that precipitate in cooler conditions), Immunodeficiency

Involvement of the skin [20, 21]

Involvement of the skin is seen in about 10% of non-hospitalised patients. Most commonly, there is a faint, widespread, non-itchy rash, which lasts for about a week. It is described as maculopapular exanthem, i.e. there are flat patches that may contain small bumpy red spots. It is thought to be directly due to the virus. This rash often appears on the trunk and upper arms first and a few days later extends to involve the face and forearms.

Other appearances of this rash include:

- Morbilliform (small, flat, measles-like patches)
- Papular (small bumps)
- Scarlatiniform (tiny spots like scarlet fever)
- Vesicular (little blisters)
- Purpuric (bruise-like)

This is in contrast to a more intense itchy maculopapular rash which appears on extensor surfaces and pressure points 7 to 10 days after treatment with beta-lactam antibiotics such as ampicillin, amoxicillin and cephalosporins. This rash indicates a 'hypersensitivity reaction' to the antibiotic. It is not a true allergy and does not occur if the antibiotic is given later on in the absence of EBV infection. There is also a variety of less common skin conditions associated with EBV infection, including:

- Gianotti-Crosti syndrome (infantile papular acrodermatitis)
- Erythema multiforme
- Erythema nodosum
- Urticaria including cold urticaria
- Urticarial vasculitis
- Acrocyanosis (bluish hands and feet)
- Annular erythema
- Pityriasis lichenoides
- Palmar dermatitis
- Genital ulceration
- Chronic bullous disease of childhood (linear IgA bullous dermatosis)
- Hairy leukoplakia
- Hydroa vacciniforme

Diagnosis

The most commonly used diagnostic criterion is the presence of 50% lymphocytes with at least 10% atypical lymphocytes (large, irregular nuclei), while the person also has fever, pharyngitis and adenopathy. Furthermore, it should be confirmed by a serological test.[9] The atypical lymphocytes resembled monocytes when they were first discovered, thus the moniker "mononucleosis" was coined. Diagnostic tests are used to confirm infectious mononucleosis but the disease should be suspected from symptoms prior to the results from hematology. These criteria are specific; however, they are not particularly sensitive and are more useful for research than for clinical use. Only half the patients presenting with the symptoms held by mononucleosis and a positive heterophile antibody test (monospot test) meet the entire criteria. One key procedure is to differentiate between infectious mononucleosis and mononucleosis-like symptoms. There have been few studies on infectious mononucleosis in a primary care

environment; the best of which studied 700 patients of which 15 were found to have mononucleosis upon a heterophile antibody test. More useful in a diagnostic sense are the signs and symptoms themselves. The presence of splenomegaly, posterior cervical adenopathy, axillary adenopathy and inguinal adenopathy are the most useful to suspect a diagnosis of infectious mononucleosis. On the other hand, the absence of cervical adenopathy and fatigue are the most useful to dismiss the idea of infectious mononucleosis as the correct diagnosis. The insensitivity of the physical examination in detecting splenomegaly means that it should not be used as evidence against infectious mononucleosis. In the past the most common test for diagnosing infectious mononucleosis was the heterophile antibody test which involves testing heterophile antibodies by agglutination of guinea pig, sheep and horse red blood cells. As with the aforementioned criteria, this test is specific but not particularly sensitive (with a false-negative rate of as high as 25% in the first week, 5-10% in the second and 5% in the third). 90% of patients have heterophile antibodies by week 3, disappearing in under a year. The antibodies involved in the test do not interact with the Epstein-Barr virus or any of its antigens.[23] More recently, tests that are more sensitive have been developed such as the Immunoglobulin G (IgG) and Immunoglobulin M (IgM) tests. IgG, when positive, reflects a past infection, whereas IgM reflects a current infection. When negative, these tests are more accurate in ruling out infectious mononucleosis. However, when positive, they feature similar sensitivities to the heterophile antibody test. Therefore, these tests are useful for diagnosing infectious mononucleosis in people with highly suggestive symptoms and a negative heterophile antibody test. Another test searches for the Epstein-Barr nuclear antigen,

while it is not normally recognizable until several weeks into the disease and is useful for distinguishing between a recent-onset of infectious mononucleosis and symptoms caused by a previous infection. Elevated hepatic transaminase levels is highly suggestive of infectious mononucleosis, occurring in up to 50% of patients.[24]

Treatment

Infectious mononucleosis is generally self-limiting and only symptomatic and/or supportive treatments are used.[25] Rest is recommended during the acute phase of the infection, but activity should be resumed once acute symptoms have resolved. Nevertheless heavy physical activity and contact sports should be avoided to mitigate the risk of splenic rupture, for at least one month following initial infection and until splenomegaly has resolved, as determined by ultrasound scan.[26] In terms of pharmacotherapies, acetaminophen/paracetamol or non-steroidal anti-inflammatory drugs (NSAIDs) may be used to reduce fever and pain. Prednisone, a corticosteroid, is commonly used as an anti-inflammatory to reduce symptoms of pharyngeal pain,odynophagia, or enlarged tonsils, although its use remains controversial.[27] Intravenous corticosteroids, usually hydrocortisone or dexamethasone, are not recommended for routine use[28] but may be useful if there is a risk of airway obstruction, severe thrombocytopenia, or hemolytic anemia.[29] There is little evidence to support the use of aciclovir, although it may reduce initial viral shedding. However, the antiviral drug valacyclovir has recently been shown to lower or eliminate the presence of the Epstein-Barr virus in subjects afflicted with acute mononucleosis, leading to a significant decrease in the severity of symptoms.[30] Antibiotics are not used as they are ineffective against viral infections. The antibiotics ampicillin and later the related amoxicillin[31] are relatively contraindicated in the case of any coinciding bacterial infections during mononucleosis because their use precipitates a non-allergic rash close to 99% of the time.^[30] In a small percentage of cases, mononucleosis infection is complicated by co-

infection with streptococcal infection in the throat and tonsils (strep throat). Penicillin or other antibiotics (with the exception of the two mentioned above) should be administered to treat the strep throat. Opioid analgesics are also relatively contraindicated due to risk of respiratory depression.[32]

Vaccine Development

A vaccine against EBV which prevents primary EBV infection should be able to control both BL and NPC. Such a vaccine must be given early in life. Such a vaccine would also be useful in seronegative organ transplant recipients and those developing severe IM, such as the male offspring of X-linked proliferative syndrome carriers.[33] The antigen chosen for vaccine development is the MA antigen gp 340/220 as antibodies against this antigen are virus neutralizing. Inoculation of cotton top tamarins by purified gp 340/220 was able to protect the animals by subsequent virus challenge. [34]

Conclusion

Infection by EBV is more common in developing countries where sanitation, hygiene and cooking are not as sterile as in developed countries. Pre chewed food and shared saliva lead to a much higher incidence of infection. Infectious mononucleosis is generally self-limiting and only symptomatic and supportive treatments are used. Rest is recommended during the acute phase of the infection, Nevertheless heavy physical activity and contact sports should be avoided to mitigate the risk of splenic rupture. As the infection can cause multiorgan involvement in chronic phase, it is necessary to control the disease as early as possible. Antibiotics does not find place in the treatment but valacyclovir is the drug of choice. Vaccine is also available and should be used to prevent the epidemic of Infectious mononucleosis.

References

- [1] E. Pfeiffer, Drüsenfieber. Jahrbuch für Kinderheilkunde und physische Erziehung, Wien, **1889**, 29: 257-264.
- [2] NIAID fact sheet "Epstein-Barr Virus" <http://www.niaid.nih.gov/factsheets/ebv.htm>.
- [3] Niederman, J.C, Evans, A.S. *Viral Infections of Humans: Epidemiology and Control*. New York: Plenum, **1997**, 253-283.
- [4] G Klein, PG Medveczky, H Friedman, M Bendinelli, *Herpesviruses and Immunity*. , eds. New York: Plenum, **1998**; 165-190.
- [5] AS Evans, NE Mueller, *Viral Infections of Humans: Epidemiology and Control*. New York: Plenum, **1997**, 895-933.
- [6] Ebell MH "Epstein-Barr virus infectious mononucleosis". *American Family Physician* , **October 2004**, 70 (7): 1279–87. .
- [7] Ghosh, K Amit, Habermann, Thomas . Mayo Clinic Internal Medicine Concise Textbook. Informa Healthcare, **2007**, pp.125-130
- [8] T Sairenji, T. Kurata, "Immune responses to Epstein-Barr viral infection." *Herpesviruses and Immunity*. , eds. New York: Plenum, **1998**; 191-206.
- [9] J Uchida, T Yasui, *Science* **1999**; 286: 300-303.
- [10] AB Rickenson, , E Kieff. "Epstein-Barr Virus." *Fields Virology 3rd. Edition*. Philadelphia: Lippincott, **1996**; 2402

- [11] Sugden, Kieff, Rickinson and Kieff,' Chapter 74 of Fields , *Virology*, 3rd Edition Chapter 75 of Fields ,*Virol.* **1994**,5:197-205.
- [12] Harrison's Principles of Internal Medicine 16th ed, Kasper et al, c **2005**,4: 122-125.
- [13] I Hickie, T Davenport, D Wakefield, *BMJ.* **2006 Sep** 16;333(7568):575
- [14] MH Beers, RS Porter, TV Jones. The Merck manual of diagnosis and therapy. 18th ed. Whitehouse Station (NJ): Merck Research Laboratories; **2006**,102-106.
- [15] The Utah Department of Health, Bureau of Epidemiology August **2001**, (801) 538-6191.
- [16] C Hurt, D Tamaro. *Am J Med.* **2007** Oct;120(10):911.e1-8.
- [17] HB Jenson, RM Kliegman Epstein-Barr Virus. In,eds. Nelson Textbook of Pediatrics. 18th ed. Philadelphia, Pa: Saunders Elsevier; **2007**:chap 251.pp. 321-326.
- [18] Harrison's Principles of Internal Medicine. 16th Ed. **2005**, 144-150.
- [19] JL Bologna, JL Jorizzo, JL Rapini. *Dermatology*, 1st Edition **2003**,11:135-145.
- [20] B Kagan, *Western Journal of Medicine* **1977**,126 (4): 333-335.
- [21] RJ Hoagland. *Primary care* **June 1975** ,2 (2): 295-307.
- [22] H Mark,MH Beers, RS, Porter ,editors. ed. *The Merck manual of diagnosis and therapy* (18th ed.).Whitehouse Station (NJ):Merck Research Laboratories **2006**,911910-18-2.
- [23] <http://www.ncemi.org/cse/cse0314.htm>
- [24] B Candy, M Hotopf, *Cochrane Database Sys Rev* **2006**,3 (4): CD004402.
- [25] Antibiotic Expert Group. Therapeutic guidelines: Antibiotic. 13th ed. North Melbourne: Therapeutic Guidelines; **2006**, 189-196.
- [26] Infectious Mononucleosis". WebMD. **January 24, 2006**.Retrieved 2006-07-10.
- [27] D Torre, R Tambini . *Scand. J. Infect. Dis.* **1999**,31 (6): 543-7.
- [28] HH Balfour, KM Hokanson, RM Schacherer, et al. *J. Clin. Virol.* **2007**,39 (1): 16-21.
- [29] Simon et al. *International Pediatrics* **March 2003**,18 (3): 164-169.
- [30] AB Rickinson, E Kieff,. "Epstein-Barr Virus." *Fields Virology, 3rd edition.* Fields, eds. Philadelphia: Lippincott-Raven, **1996**; 2397-2446.
- [31] R Khanna, S Bell, M Sherritt, et al. *Proc. Nat. Acad. Sci. U.S.A.* **1999**; 96(18): 10391-10396.