



Scholars Research Library

Archives of Applied Science Research, 2010, 2 (1) 14-18
(<http://scholarsresearchlibrary.com/archive.html>)



ISSN 0975-508X
CODEN (USA) AASRC9

Hepatoprotective activity of *Beta vulgaris* against CCl₄ induced acute hepatotoxicity in rats

*Ranju Pal¹, Kundlik Girhepunje¹, Hitesh Gevariya¹, Thirumoorthy N.²

¹Shree Leuva Patel Trust Pharmacy Mahila College, Amreli, Gujarat

²Patlolla Ramkrishna Reddy College of Pharmacy, Hyderabad (A.P.)

Abstract

Beta vulgaris commonly known as beet root belongs to family Amaranthaceae, has been used in folk medicine to treat a wide variety of ailments like fever, constipation, cancer and diabetes. Modern research is investigating in further detail how beet extracts could be used to protect normal and diabetic liver, however no systemic scientific study is available on its effect as hepatoprotective agent. Phytochemical studies of *Beta vulgaris* root reveal the presence of flavonoids, carbohydrate, betain, neobetain and anthocyanin pigments. The present study was made to evaluate the effect of ethanolic extract of *Beta vulgaris* (EEBV) root against CCl₄-induced hepatic damage in rats. Hepatoprotective activity of EEBV was studied by estimating serum enzyme levels of aspartate aminotransferase (AST), alanine aminotransferase (ALT), alkaline phosphatase (ALP), total protein and bilirubin. The treatment with EEBV showed significant (P<0.01) reduction of CCl₄ induced elevated serum levels of enzyme activities and bilirubin with parallel significant (P<0.01) increase in total protein, indicating the extract could preserve the normal functional status of the liver. Histology of the liver sections of the animals treated with the extracts showed the presence of normal hepatic cords, absence of necrosis and fatty infiltration, which further evidenced the hepatoprotective activity.

Key words: Hepatoprotective activity, *Beta vulgaris*, hepatotoxicity, enzyme activity, biochemical studies.

Introduction

The liver plays an astonishing array of vital functions in the maintenance, performance and regulating homeostasis of the body. It is involved with almost all the biochemical pathways to growth, fight against disease, nutrient supply, energy provision and reproduction. Liver diseases are a serious health problem. Therefore, the maintenance of a healthy liver is vital to overall health and well being [1]. Unfortunately, the liver is often abused by environmental toxins, prescription and over-the-counter drug use, which can damage the liver and lead to hepatitis, cirrhosis and liver disease [2]. In the absence of reliable liver protective drugs in

allopathic medical practices, herbs play a role in the management of various liver disorders. Numerous medicinal plants and their formulations are used for liver disorders in ethnomedical practices and in traditional system of medicine in India. However, we do not have satisfactory remedy for serious liver disease; most of the herbal drugs speed up the natural healing process of liver [3]. So the search for effective hepatoprotective drug continues. *Beta vulgaris* belongs to family amaranthaceae, has been used in folk medicine to treat a wide variety of ailments like fever, constipation, cancer and diabetes [4]. Literature reviews indicated that the hepatoprotective activity of these species has not been clinically evaluated so far. The objective of the present study was framed to determine the effect of ethanolic extracts of *Beta vulgaris* root on circulating liver enzyme levels, serum bilirubin and protein at liver injury, during the earliest phases of implantation in rats induced with CCl₄ hepatotoxicity.

Materials and Methods

Preparation of plant extract

The roots of *Beta vulgaris* was collected from the local market of Gwalior. The plant was authenticated by the Botany Department of agricultural University, Gwalior. The chopped roots were extracted with ethyl alcohol using Soxhlet apparatus and concentrated in-vacuo. Approximately, 6.5 g of dried ethanolic extract of *Beta vulgaris* (EEBV) was obtained from 500 g of root material. The extract was suspended in 1% gum acacia and used for studying hepatoprotective activity [5].

Experimental Models

Male albino rats weighing between 150 and 175 g were used in this study. They were maintained at standard housing conditions and fed with commercial diet (Hindustan Lever Ltd., Mumbai) and provided with water ad libitum during the experiment. The institutional animal ethical committee (949/a/06/CPCSEA) permitted the study. The rats were divided into five groups, each group consisting of six animals. Group I: served as control; Group II: received CCl₄ (1.25 ml/kg) by oral route, Group III: received silymarin (2.5 mg/100 g), Group IV: receive EEBV extract (250 mg/kg; po) once daily, for 14 days. On the 15th day, CCl₄ was given by oral route 30 min after the administration of silymarin and EEBV. All the rats were anaesthetized with diethyl ether. Blood was collected by sino-orbital puncture and serum separated was analyzed for various biochemical parameters [6].

Estimation of biochemical parameters

After 36 h of CCl₄ administration all the animals were sacrificed on day 15 under light ether anaesthesia. The blood samples were collected separately by carotid bleeding into sterilized dry centrifuge tubes and allowed to coagulate for 30 min at 37°C. The clear serum was separated at 2000 rpm for 15 min and biochemical investigations were carried out to assess liver function [6]. Biochemical parameters like serum aspartate transaminase (AST) and alanine transaminase (ALT) were assayed by standard methods [7]. The activity of alkaline phosphatase [8], levels of total bilirubin [9] and protein [10] were estimated. The total bilirubin in serum was determined using the method of Jendrassik et al. Statistical significance was determined using one-way analysis of variance (ANOVA) by comparing the results obtained for each experimental group i.e., normal control, CCl₄ control, silymarin and EEBV administered albino rats. The difference in results between groups was considered as significant if $P < 0.05$. The results are expressed as mean \pm SEM of six animals from each group.

Histopathology

After draining the blood, liver samples were excised, washed with normal saline and processed separately for histological observations. Initially, the materials were fixed in 10% buffered neutral formalin for 48 h and then with bovine solution for 6 h. Paraffin sections were taken at 5mm thickness, processed in alcohol–xylene series and were stained with alum hematoxylin and eosin. The sections were examined microscopically for histopathological changes [11].

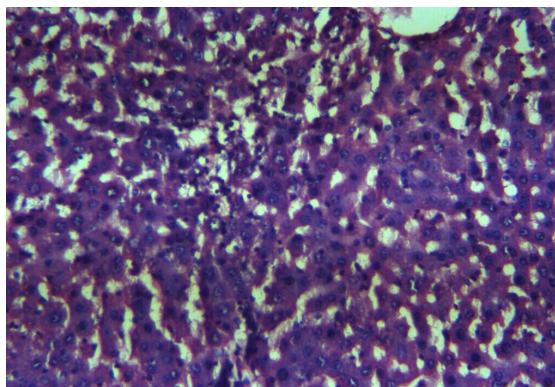


Fig 1. Section of the liver tissue of control rats showing normal histology, portal triad consisting of portal vein, portal artery, hepatic duct (H & E, 100 x)

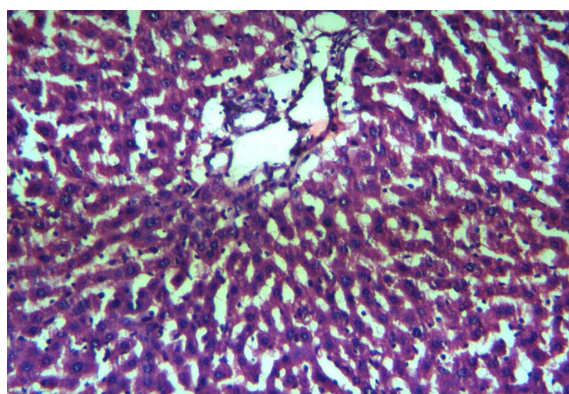


Fig 2. Section of the liver tissue of rats treated with CCl₄ showing necrosis and fatty vacuole (H & E, 100 x)

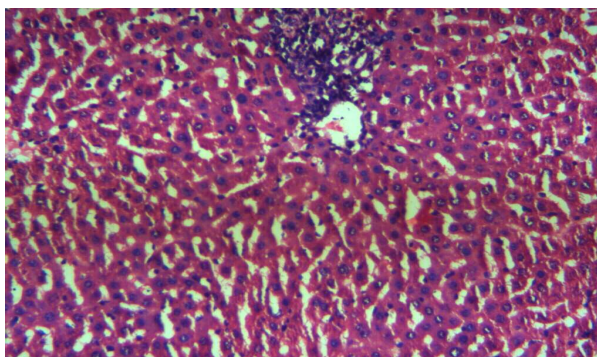


Fig 3. Section of the liver tissue of EEBV treated rat showing normal arrangements of hepatocytes around the central vein, portal absence of necrosis and fatty vacuoles(H & E, 100 x)

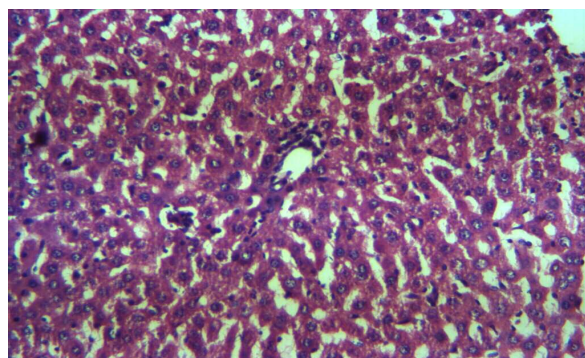


Fig 4. Section of the liver tissue of silymarin treated rat showing normal arrangements treated rat showing normal hepatocytes, portal triad showing portal vein, portal artery and hepatic duct (H & E, 100 x)

Results and Discussion

Table 1 shows the effect of EEBV on CCl₄ induced hepatotoxicity in rats. Rats induced with CCl₄ showed a significant reduction ($P < 0.05$) in the levels of protein and significant increase in the levels of bilirubin and also the activities of AST, ALT and ALP. Treatment with alcoholic extract of EEBV for a period of 10 days significantly restores the levels of the liver function biochemistry similar to that of standard drug silymarin.

Table 1. Effect of *Beta vulgaris* root extract (EEBV) on CCl₄-induced hepatotoxicity in rats

Group (n)	Bilirubin	Protein	A ST (IU/l)	ALT (IU/l)	ALP (IU/l)
Control	0.70±0.03	123.0±4.10	45.3±0.80	131.05±1.98	160.6±3.79
CCl ₄ treated	2.12±0.01*	251.0±5.31 *	260.5±3.8 *	217.3±4.5*	388.6±18.25
CCl ₄ + Silymarin	0.8±0.07 **	109.6±5.20 **	81.3±9.10 **	138.0±2.17 **	218.5±5.47 **
CCl ₄ + EEBV	0.83±0.01 **	133.3±3.41**	67.0±5.79 **	115.3±1.16 **	292.6±5.32 **

Values are expressed as mean ± SEM, $N = 6$ animals in each group, * $P < 0.001$; ** $P < 0.01$ when compared with control.

Histological profile of the control animals showed normal hepatocytes (Fig. 1). Group II animals exhibited intense centrilobular necrosis, vacuolization and macrovesicular fatty change (Fig. 2). The sections of liver taken from the animals treated with standard drug silymarin showed the hepatic architecture, which was similar to that of control (Fig.3). The animals treated with ethanol extract exhibited significant liver protection against the toxicant as evident by the presence of normal hepatic cords, absence of necrosis and lesser fatty infiltration (Fig. 4).

Carbon tetrachloride has been widely used to induce experimental hepatic damage [12]. It induces liver cell necrosis and apoptosis and can be used to induce hepatic fibrosis or cirrhosis by repetitive administration. Liver is rich in transaminases, which increase in patients with acute hepatic diseases. AST, which is slightly elevated by cardiac necrosis, is a more specific indicator of liver disease [13,14]. ALT, AST and ALP are the specific markers

to assess hepato-cellular damage. Estimation of the serum total bilirubin, protein and alkaline phosphatase activity is one of the most widely used means of measuring hepato-cellular injury. In this study, a significant increase in the levels of bilirubin with significant increase in the activities of AST, ALT and ALP but, significant decrease in the levels of protein was observed. The elevation of enzyme activities and altered levels of bilirubin and protein are due to increased production of free radicals, which initiate lipid peroxidation leads to cellular damage. In the present study, EEBV administration possesses significant effect on CCl₄ induced hepatotoxicity. Decrease in the levels of serum bilirubin, the activities of AST, ALT and ALP with significant increase in protein after treatment with EEBV indicated the effectiveness of the extract against CCl₄ induced hepatotoxicity. The hepatoprotective effect of EEBV may be due to presence of its chemical contents.

Conclusion

These observations suggest that ethanolic extract of *Beta vulgaris* exhibited significant hepatoprotective activity. So the hepatoprotective effect of extract may be due to its flavonoid content. Further, this study might highlights phytochemical profile of *Beta vulgaris* and finds the effective leads from natural resources for the desired therapeutic benefit.

Acknowledgment

The authors are grateful to Principal and Staff of Shree Leuva Patel Trust Pharmacy Mahila College, Amreli, for providing facilities to carry out the research work.

References

- [1] F.M. Ward and M.J. Daly, Hepatic Disease. In: Clinical Pharmacy and Therapeutics (Walker R. and C.Edwards Eds.), Churchill Livingstone, New York, **1999**, 195-212.
- [2] A. Sharma, K.K. Chakraborti and S.S. Handa, Anti-hepatotoxic activity of some Indian herbal Formulations, **1991**, 77-81.
- [3] Dwijendra Singh, S. Sucheta and Mehta, *Current Science*, **2003**, 84, 1186-1187.
- [4] T. Kujala, J. M. Lopenen, K. D. Klika, and K. Pihlaja, *Journal of Agriculture and Food Chemistry*, **2000**, 48, 5338-5342.
- [5] P. Murugaian, *Research Journal of Agriculture and Biological Sciences*, **2008**, 4(6), 685-687.
- [6] K.K. Pillai, V. kapur, S.Z. hussian and D.K. Balani, *Indian Journal of Pharmacology*, **1994**, 26, 35 – 40.
- [7] S.H. Yatzidis, *Nature*, **1960**, 186, 79-80.
- [8] D.W. Moss, D.N. Baron, P.G. Walker and J.H. Wilkinson, *J. Clin. Pathol.*, **1971**, 24, 740-743.
- [9] H.T. Mallay and K.A. Evelyn, *J. Biol. Chem.*, **1937**, 119, 481-484.
- [10] O.H. Lowry, N.J. Rosebrough, A.L. Farr and R.J. Randall, *J. Biol. Chem.*, **1951**, 193, 265-275.
- [11] A.E Galigher, E.N Koyloff, Essential of practical microtechnique, Philadelphia, Lea and Febiger, **1971**.
- [12] R.O. Recnagel, *Trends Pharmacol Sci.*, **1983**, 4, 129-131.
- [13] G.F. Shi and Q. Li, *World J. Gastroenterol*, **2005**, 11, 268-271.
- [14] M.L. Chang, C.T. Yeh, P.Y. Chang and J.C. Chen, *World J. astroenterol*, **2005**, 11, 4167-4172.