

One of the Properties of Honey in Wound Healing Is Prevention of Autolysis

Godwin Avwioro¹, Julius Bankole², Sina Iyiola³, Temidayo Avwioro⁴, Gift Akinola²

¹Faculty of Basic Medical Sciences, Delta State University, Abraka, Nigeria

²Department of Medical Laboratory Science, Ambrose Alli University, Ekpoma, Nigeria

³Department of Histopathology, Obafemi Awolowo University Teaching Hospital, Ile Ife, Nigeria

⁴Department of Nursing, Obafemi Awolowo University Teaching Hospital, Ile Ife, Nigeria

Abstract

The preservative property of honey on animal tissues in histological techniques was investigated in order to establish a relationship with its wound healing property and to determine if the wound healing property is as a result of prevention of autolysis or prevention of putrefaction. Tissues taken from the heart, kidney and brain were preserved in undiluted pure honey for between one to thirty days. The tissues were then processed by the paraffin wax method, sections cut at 4 μ with the rotary microtome and stained with haematoxylin and eosin. The sections were compared with formalin fixed tissues taken from the same source with the experimental tissues. Autolysis and putrefaction were not seen in tissues preserved in honey for up to 30 days. The tissues became hard between the second and third days of preservation in honey. Microscopically, nuclear and cell sizes as well as the overall tissue architecture were similar to tissue sections preserved in 10% formol saline for the same period. The staining reactions were also similar to those fixed in 10% formol saline. We conclude that the wound healing property of honey does not depend on its antibiotic property alone, but also on the ability of honey to prevent autolysis and its ability to harden tissue.

Key words: Honey, preservation, tissue processing

INTRODUCTION

Honey is produced from many floral sources and its content and activity vary with its origin and processing technique. Histological studies of honey applied to wounds have been reported to be safe [1,2] as it reduces inflammation in deep [1] and superficial [3] burns as well as in wounds [4]. At a concentration of 1%, it stimulates growth of monocytes in cell cultures to release cytokines, tumour necrosis factor (TNF)-alpha, interleukin (IL)-1 and IL-6, which activate the

immune response to infection [5]. The proliferation of peripheral blood B-lymphocytes and T-lymphocytes in cell culture has also been stimulated by honey at concentrations as low as 0.1%; and phagocytes are activated by honey at concentrations as low as 0.1% [6]. The bacteria destroying activity of macrophages may have been assisted by the carbohydrate content of honey principally, glucose and fructose [7] and by its pH [8] which is between 3 and 4. Honey is said to have an inhibitory effect to several species of bacteria including aerobes and anaerobes, gram-positives and gram-negatives [9] and an antifungal action on some yeasts and species of *Aspergillus* and *Penicillium* [9], as well as some dermatophytes [10]. Wounds infected with *Pseudomonas*, showing resistance to several antibiotics, have been rapidly cleared of infection with honey and allowing successful skin grafting [11]. Application of honey to open wounds has been reported to be soothing [12], to relieve pain [12], and with no adverse effects [13]. Histochemical reactions are sometimes influenced by the choice of a fixative because they react with tissue constituents to either alter their configuration to give new products or to introduce artifacts into the tissues [14]. Tissues have been preserved with several chemicals that are capable of preventing autolysis and putrefaction. Generally, fixatives, which contain acetic acid or those with low pH, do not favour the staining of the cytoplasm [15]. Formalin a major constituent of 10% formol saline supports many staining techniques, Carnoy's fluid, which contains alcohol and acetic acid is a good fixative for chromosome studies. Zenker's fluid is good for the trichrome methods for collagen fibres while Helly's fluid is said to be a good fixative for micro-anatomical and cytological studies [16]. Honey contains lysozymes [17], and lysozymes themselves are hydrolytic enzymes active at acid pH against several bacteria species [15]. Honey also contains several minerals and trace elements such as potassium, sodium, chlorine, calcium, magnesium, magnesium, iron, manganese, copper, magnesium, sulfur and silicon (as SiO₂), and chromium, lithium, nickel, lead, tin, zinc, osmium, beryllium, vanadium, zirconium, silver, barium, gallium, bismuth, gold, germanium and strontium [7]. Vitamins such as B1 (Thiamin), Riboflavin, Niacin, B6 (Pyridoxine), Pantothenic acid, B12 and C (Ascorbic acid) are also found in honey [7]. It has also been shown that honey contains seven tetracycline derivatives, fatty acids, lipids, amylases and ascorbic acid [18-20], and hydrogen peroxide [21-23] which may account partly for its putrefactive property. The aim of this study was to establish a relationship between wound healing properties of honey and its property of preventing autolysis and putrefaction.

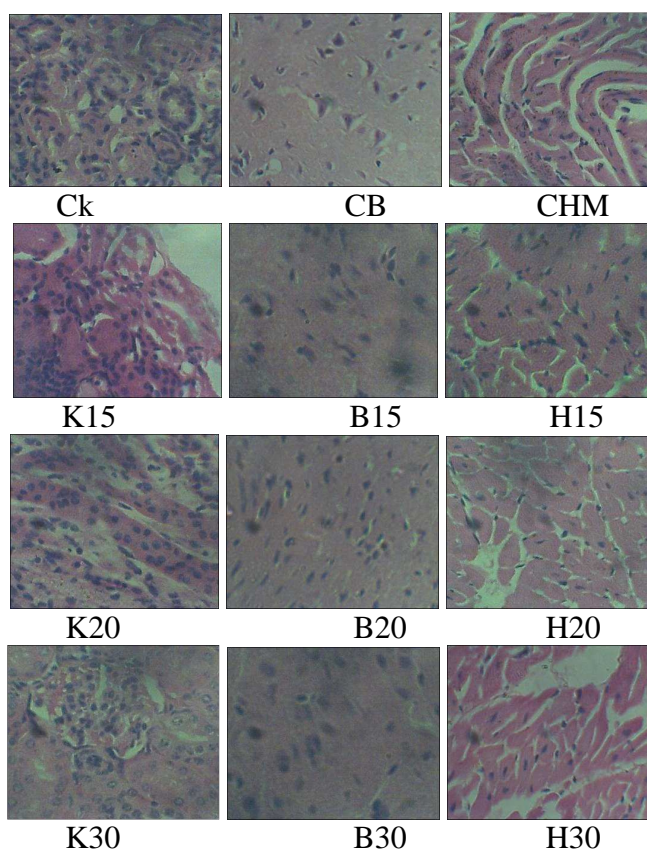
MATERIALS AND METHODS

An adult Wister rat on normal diet was sacrificed through cervical dislocation. Tissues were taken from the heart, kidney and brain. Each tissue was cut into 60 pieces to make a total of 180 pieces, each about 1 mm thick. They were divided into two equal halves consisting of 90 pieces each; i.e. two sets of heart tissue consisting of 30 pieces each, labelled Heart Control 1-30 and Heart Test 1-30; two sets of kidney tissue consisting of 30 pieces each, labelled Kidney Control 1-30 and Kidney Test 1-30; and two sets of brain tissue consisting of 30 pieces each, labelled Brain Control 1-30 and Brain Test 1-30. The controls were grouped together and immediately fixed in 10% formol saline. The tests were similarly grouped together and immediately immersed in pure honey. A set consisting of one piece each of liver, kidney and brain tissues was removed from the honey daily and transferred to 10% formol saline until completion in 30 days. The control tissues were similarly treated for 30 days. The tissues were then processed by the paraffin wax method through dehydration in graded concentrations of alcohol, clearing in xylene and infiltration in paraffin wax. Tissues were finally embedded in paraffin wax and sections cut at 4 μ with the rotary microtome. The sections were stained with haematoxylin and eosin [15] and examined with the X40 objective of the microscope.

RESULTS

All sections from tissues fixed in pure honey appeared preserved after 30 days in the honey. The nuclear and cytoplasmic staining as well as the general connective tissue staining was similar to tissues fixed in 10% formol saline. Cutting qualities in paraffin wax processed tissues were also similar to 10% formol saline as shown in plate 1.

Plate 1: Photomicrographs of control sections fixed in 10% formol saline and honey treated tissue sections from 15 days to 30 days.



Key:

CK- Control kidney section in 10% formol saline, CB- Control brain section in 10% formol saline, CHM- Control heart muscle section in 10% formol saline.

K15- Kidney 15 days in honey, B15- Brain 15 days in honey, H15- Heart 15 days in honey, K20- Kidney 20 days in honey, B20- Brain 20 days in honey, H20- Heart 20 days in honey, K30- Kidney 30 days in honey, B30- Brain 30 days in honey, H30- Heart 30 days in honey,

When compared with control sections, the honey treated tissue sections (K15, K20, K30, B15, B20, B30, H15, H20 and H30) did not show significant signs of autolysis or putrefaction. Cell and nuclear sizes as well as the overall tissue architecture and staining reactions were similar to the formalin fixed tissue sections.

Table 1 Microscopic appearance of some H&E stained tissues preserved in pure undiluted honey compared with formalin fixed tissues

Tissue type	General stain uptake	Nuclear and cytoplasmic appearance and sizes	General tissue architecture
Heart, Brain, Kidney	Similar to formalin fixation	Similar to formalin fixation	Similar to formalin fixation

DISCUSSION

For several centuries, honey has been used as a medicine particularly for the treatment of wounds which contain several species of bacteria including aerobes and anaerobes, gram-positives and gram-negatives [9] and some yeasts and species of *Aspergillus* and *Penicillium* [9], as well as some dermatophytes [10] without adverse effects [13]. Apart from these antibiotic properties, honey has been found to prevent autolysis as tissues put in it for up to 30 days did not show any sign of autolysis and autolysis. The tissue hardening property makes it similar in action to fixatives which act by hardening tissues. Although it has been said that honey that is not well filtered may contain various artifacts in it, including viable spores such as clostridia which may cause false positive reactions [25], the honey used in this experiment could not be filtered because of its viscosity. However, it has been suggested that honey can be treated with gamma-irradiation to make it sterile as all organisms will be killed by this treatment [26]. The fact that tissues preserved in pure honey for 30 days did not show any sign of deterioration makes the wound healing property of honey to be beyond its antibiotic property. Consideration should therefore be given to its anti-autolytic property as well as its growth promoting property as evidenced by the growth of monocytes and lymphocytes in cell cultures containing honey [5,6]. Generally, fixatives which contain acids or those with low pH do not favour preservation of cytoplasmic constituents, but they are good nuclear fixatives. Cytoplasmic fixatives do not contain acids [15]. Honey contains several minerals, trace elements and vitamins as well as carbohydrates and acids principally glucose and fructose [7] and ascorbic acid respectively. The latter may account for its low pH [8] of between 3 and 4, hence by extension a good nuclear fixative as seen in haematoxylin and eosin stained preparations of tissue sections preserved in honey. We conclude that the wound healing property of honey does not depend only on its antibiotic property, but also on its ability to prevent autolysis.

REFERENCES

- [1] TJ Postmes; MMC Bosch; R Dutrieux; J van Baare. In: Mizrahi A, Lensky Y, editors. *Bee Products: Properties, Applications and Apitherapy*. New York: Plenum Press, **1997**, 27-37.
- [2] M El-Banby; A Kandil; G Abou-Sehley; ME El-Sherif; K Abdel-Wahed. *Fourth International Conference on Apiculture in Tropical Climates, Cairo*. **1989**
- [3] F Burlando. Sull'azione terapeutica del miele nelle ustioni. *Minerva Dermatol* **1978**, 113, 699-706.
- [4] A Oryan; SR Zaker. *Veterinarmed* **1998**, 45, 181-8.
- [5] A Tonks; RA Cooper; AJ Price; PC Molan; KP Jones. *Cytokine* **2001**, 14, 240-2.
- [6] N Abuharfeil; R Al-Oran; M Abo-Shehada. *Food Agric Immunol* **1999**, 11, 169-77.
- [7] EA Crane. *Book of Honey*, published in New York Charles Scribner's Sons. **1980**
- [8] GB Ryan; G Majno. *Inflammation*. Michigan: Upjohn. **1977**
- [9] PC Molan. *Bee World*. **1992** 73:5-28.
- [10] NF Brady; PC Molan; CG Harfoot. *Pharm Sci* **1977**, 2, 1-3.
- [11] C Dunford; R Cooper; P Molan. *Nurs Times* **2000**, 96, 7-9.

- [12] M Subrahmanyam. *Br J Plast Surg.* **1993**, 46, 322-3.
- [13] G Ndayisaba; L Bazira; E Habonimana; D Muteganya. *J Orthop Surg.* **1993**, 7, 202-4.
- [14] CFA Culling. *Handbook of histopathological and histochemical techniques.* 3rd Ed. Butterworths, London. **1976**, 29-61.
- [15] OG Avwioro. *Histochemistry and Tissue Pathology.* Claverianun Press. Ibadan, Nigeria. **2002**
- [16] OG Avwioro; CP Aloamaka; II Imosemi. *International Journal of Morphology.* **2005** 23, 397-398
- [17] W Mohrig; R Messner. *Acta Biologica Medica Germanica* **1993**, 21, 85-95.
- [18] M Rahmanian; A Khouhestani; H Ghavifekr; N Ter-Sarkissian; G Ionoso; AO Marzys *J Nutr Metab.* **1970**, 12, 131-5.
- [19] JH Dustmann. *Apiacta.*, **1979** 14:7-11.
- [20] SE Efem. *Br J Surg.* **1988** 75:679-81.
- [21] JW White; MH Subrs; AL Schepartz. *Biochemical Biophysical* **1963**, Acta., 73, 57-70.
- [22] DA Mossel. **1980** *Lancet* 2:1091.
- [23] LA Roth; S Kwan; P Sporns. *Journal of Food Protection* **1986**, 49, 436-44.
- [24] PC Molan; KL Allen. *J Pharm Pharmacol.***1996**, 48, 1206-9.
- [25] T Postmes; AE van den Bogaard; M Hazen. *Experientia.* **1995**, 51, 986-9.