



ISSN : 2348-1935

RESEARCH ARTICLE

Annals of Experimental Biology
2015, 3 (4):20-26

Anatomical and Histological Studies of the Small Intestine of the African Giant Rat (*Cricetomys gambianus*-Water house)- II

Nzalak, J.O.*¹, Wanmi, N², Imam, J.¹ Ali and M.N¹ Umosen, A.D¹.

¹Department of Veterinary Anatomy, Ahmadu Bello University, Zaria, Nigeria.

²Department of Veterinary Anatomy, University of Agriculture Makurdi, Benue State, Nigeria

*Corresponding e-mail: mzalakoliver@gmail.com

ABSTRACT

Forty African giant rats (AGRs), (*Cricetomys gambianus*-Waterhouse) were used for morphometric, morphologic and histologic. The rats were sacrificed according to the method of Adeyemo and Oke (1990) and the different segments of the small intestine (duodenum, jejunum and ileum) were weighed, measured and photographs taken. Transverse sections of the different segments of the small intestine were stained with Haematoxylin and Eosin for normal histological studies. The small intestine was observed to have a mean weight and length of 17.19 ± 0.30 g and 109.17 ± 28.68 cm respectively. The small intestine had three segments (duodenum, jejunum and ileum), their mean weight and length were 5.00 ± 0.11 g, 9.46 ± 0.20 g, 2.65 ± 0.07 g and 20.15 ± 0.93 cm, 72.26 ± 2.39 cm and 16.25 ± 0.37 cm, respectively. The duodenum had prominent Brunner's glands which were seen in the submucosa. Numerous villi which were finger-like were seen in the jejunum. Intestinal glands and Payer's patches were seen in the ileum.

Keywords: Anatomical, Histologic, small intestine and African giant rat (*Cricetomys gambianus*-Waterhouse).

INTRODUCTION

The African giant rat (AGR) is found in the rain forest zone where they are restricted to farmlands, grasslands and human habitations. They are frequently seen at night crossing roads, running along drains and in house compounds. They are social animals and as such several individuals live together in a burrow. They walk and run on their four legs, usually with their tails raised and are good climbers and jumpers. In Nigeria, these rodents are often incorrectly called "rabbits" or "Nigerian rabbits" [1].

In view of their abundance and size, the rodents are often eaten by the people and considered a delicacy. Their smoked carcasses are often seen in village markets. Attempts have been made to breed and rear the animal in captivity for food [2]. The rodent has a good potential for use as a laboratory animal [3] and has been shown to be a good host for the laboratory passage of *Schistosoma mansoni* and *Trypanosoma evansi* [4]. Recently, the rodent has been used to detect tuberculosis patients and to sniff out landmines in Mozambique [5]. The excessive and uncontrolled consumption of this animal poses a threat to the ultimate survival of this species and a researcher [6] had attempted to study its biology and domestication. As a contribution towards this pioneering effort, several attempts at characterization of the reproductive organs have been made [7-11]. Other works on the AGR include those on the brain [12-15]. The dietary requirement and feeding habit of the African giant rat cannot be properly understood without a detailed knowledge of the digestive system. It is also a well-known fact that the subfamily,

Cricetomyinae, exhibits food storing behavior [16] and it comprises pouched rats that obtain their common name from large storage pouches inside their cheeks. This animal collects seeds, fruits, roots and other foods on the ground pack them into the pouches and carry them to special food stores in their burrows, but all these behavioral acts appear to have been based on feeding habit in the wild. An understanding of the digestive system will aid in maintenance, domestication and preservation of wild and endangered species [16].

The morphology of the gastrointestinal tract (GIT) has been reported in a number of other animals such as the cattle, sheep, pig, horse, dogs [17], man [18], laboratory rats [19], [20] and birds [21]. Despite the features of this rat that have been studied, the small intestine is yet to be fully investigated. The only work done on the digestive system of this rodent in this part of the country is on the morphometry, morphology, histology and histochemistry of some aspect of the digestive system [22-25] and not on the small intestine.

Basic information on the morphometry, morphology and histological features of the small intestine of the African giant rat will serve as a baseline data for further research.

MATERIALS AND METHODS

Animal Source

Forty adult African giant rats, (AGR) *Cricetomys gambianus*, of both sexes were captured alive in the wild around Samaru and Bomo villages in Zaria, Kaduna State, Nigeria from January to April 2009 using metal cage traps. They were transferred into standard laboratory rat cages in the Department of Veterinary Anatomy, Ahmadu Bello University, Zaria and fed with commercial feed for a while before sacrifice. Water was given *ad libitum* during the period. The captured African giant rats were used for morphometric, morphologic and histological studies.

Morphometric studies

Forty of these rats were used for the morphometric study and each was weighed alive using a mettler balance (Model P1421) with a sensitivity of 0.1gm and the weight recorded in grams. Sex difference was not taken into consideration. Each rat was placed on a lateral recumbency and sacrificed according to [26]. An incision was made from the first cervical vertebrae up to the level of the pelvic region with the rat lying on a dorsal recumbency to show the esophagus and the content of the GIT. The entire GIT was exteriorized and the small intestine and its segments (duodenum, jejunum and ileum), were weighed and their lengths measured and recorded. All these measurement were done using a Fatzun balance (model P141 with a sensitivity of 0.01 gm), a ruler and thread (in cm), respectively.

Morphologic studies

Photographs of the live AGR were taken before sacrificing [26]. The entire GIT was exteriorized and stretched out to full length. The positions of the pancreas, gall bladder and the lobes of the liver were noted. Photographs of all the relevant segments were taken at appropriate times *insitu* and when dissected out.

Histological studies

After sacrificing the rats [26] they were opened up and tissues were collected from the small intestinal segments. The tissues were immediately fixed by complete immersion in 10% normal formalin and labeled and kept for two days. They were dehydrated through a series of graded alcohol (70%, 80%, 90%, 95% and 100%). They were later cleared in xylene and infiltrated with molten paraffin wax. Transverse sections of 5 μ thick were cut from the embedded tissues using disposable microtome knives. These sections were mounted on grease free clean glass slides and stained at room temperature using Haematoxylin and Eosin (H&E) method for routine histological studies.

Statistical Analysis

Recorded weights and lengths studied were expressed as mean \pm standard error of mean ($M \pm SEM$) using statistical package for social sciences (SPSS) version 17.

RESULTS

Morphometry.

The mean weight of the AGR was observed to be 1045.0 ± 28.06 g. The mean weight of the gastrointestinal tract was 58.18 ± 0.89 g which accounted for 5.56% of the total weight of the animal. The small intestine and its

segments (duodenum, jejunum and ileum) were 17.19 ± 0.30 g, 5.00 ± 0.11 g, 9.46 ± 0.20 g and 2.65 ± 0.07 g, accounting for 1.64%, 0.48%, 0.90% and 0.26% of the total weight of the animal, respectively. The jejunum had the highest mean weight followed by the duodenum; the ileum had the least mean weight (Table 1).

Table 1: Morphometric Features of the Digestive System of the African giant rat (AGR) (g).

Parameters	Minimum Value (g)	Maximum Value (g)	Mean \pm SEM	% body wt
Body weight	800	1400	1045.0 \pm 28.06	100
Weight of GIT	47.70	69.20	58.18 \pm 0.89	5.56
Weight of small intestine	14.00	21.00	17.19 \pm 0.30	1.64
Weight of duodenum	4.00	7.00	5.00 \pm 0.11	0.48
Weight of jejunum	6.10	12.00	9.46 \pm 0.20	0.90
Weight of ileum	2.00	3.90	2.65 \pm 0.07	0.26

n = 40, SEM = Standard Error of Mean.

The mean length of the gastrointestinal tract was found to be 213.32 ± 3.88 cm. The mean length of the small intestine and its segments (duodenum, jejunum and ileum) were found to be 109.17 ± 28.68 cm, 20.15 ± 0.93 cm, 72.26 ± 2.39 cm and 16.25 ± 0.37 cm, respectively accounting for 51.20%, 9.50%, 33.90% and 7.80% of the total length of the GIT, respectively. Jejunum had the longest mean length followed by the duodenum and finally the ileum (Table 2)

Table 2: Morphometric Features of the Digestive System of the African giant rat (cm).

Parameter	Minimum Value (cm)	Maximum Value (cm)	Mean \pm SEM	% body wt
Length of GIT	169.0	264.50	213.32 \pm 3.88	100.00
Length of small intestine	81.00	141.00	109.17 \pm 28.68	51.20
Length of duodenum	12.00	33.00	20.15 \pm 0.93	9.50
Length of jejunum	55.00	95.00	72.26 \pm 2.39	33.90
Length of the ileum	11.00	20.00	16.25 \pm 0.37	7.80

n = 40, SEM = Standard Error of Mean.

Morphology

The small intestine was made up of the duodenum, the jejunum and the ileum. The duodenum was observed to be the first part of the small intestine and occupied the right dorso-lateral part of the abdominal cavity and had the largest diameter (Plates I, II and III). The jejunum was the distal continuation of the duodenum and was observed to be the longest part. It was differentiated from the duodenum by its folding nature and was made up of many folds held together by mesentery. The jejunum was related craniomedially to the caecum (Plates I, II). The ileum was observed to be the distal continuation of the jejunum with the same diameter as the jejunum and only differed from the jejunum by the absence of folds seen on the jejunum (Plate III).

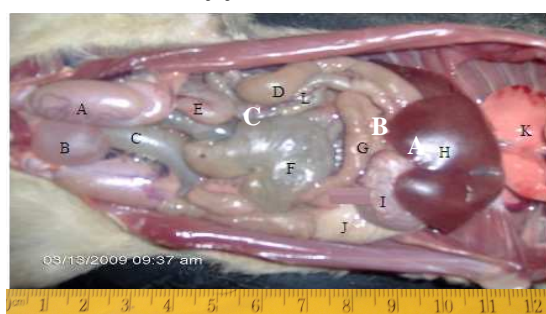


Plate I: Abdominal viscera of the AGR showing the testes (A), the urinary bladder (B), the rectum (C), the duodenum (D), the jejunum (E), the caecum (F), the transverse colon (G), the liver (H), the glandular stomach (I), the non glandular stomach (J), the lungs (K) and descending colon (L).

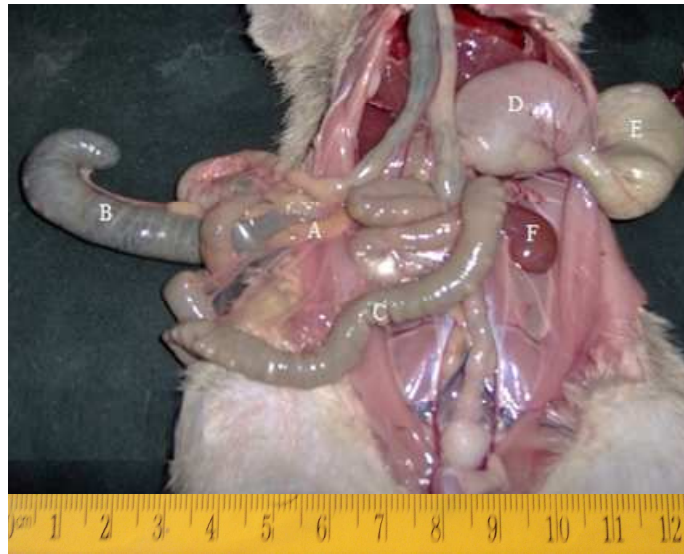

Plate II: The reflected part of the GIT of the AGR showing the Pancreas(A), the caecum (B), the duodenum (C), the glandular stomach (D), the non glandular stomach (E) and the kidney (F).

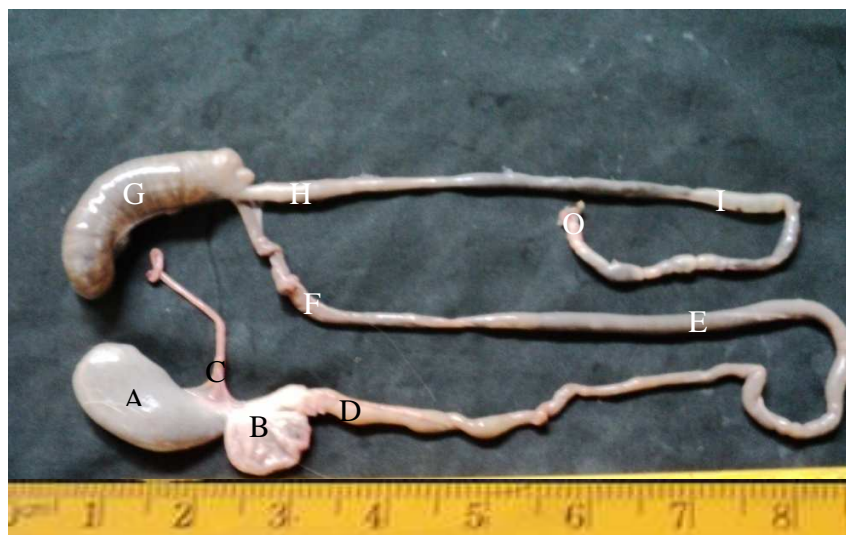


Plate III: The GIT of the AGR showing the non glandular stomach, the glandular stomach (B), the esophagus (C), the duodenum (D), the jejunum (E), the ileum (F), the caecum (G), the colon (H), the rectum (I) and the anal opening (O).

Histology

The small intestine had three segments (duodenum, jejunum and ileum). These three segments had many common histological features like the villi and some minor structural differences (Plates I, II, and III). The duodenum had intestinal villi which were seen in the mucosa. Intestinal glands (Brunner's) were seen in the submucosa and were the major distinguishing features observed in the duodenum (Plate I). The jejunum was observed to have long leaf-like villi, which were mucosa projections with numerous intestinal glands (*crypts of Lieberkuhn*) that opened into pits between the bases of the villi and penetrated the mucosa as far as the muscularis (Plate II). The ileum was observed to have villi and the intestinal glands around the mucosa. There were Payers patches in the submucosa, while the tunica muscularis had longitudinal muscles (Plate III).

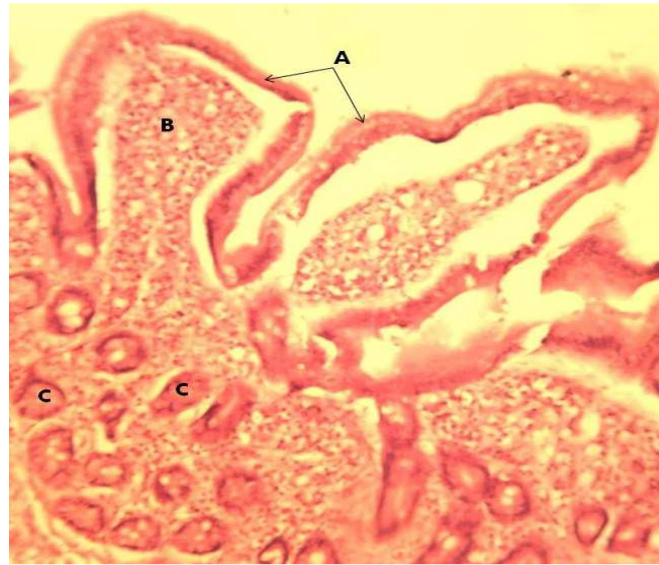

Plate I: Transverse section of the duodenum showing the epithelium (A), villus (B) and the Brunner's glands (C). H&E x100.

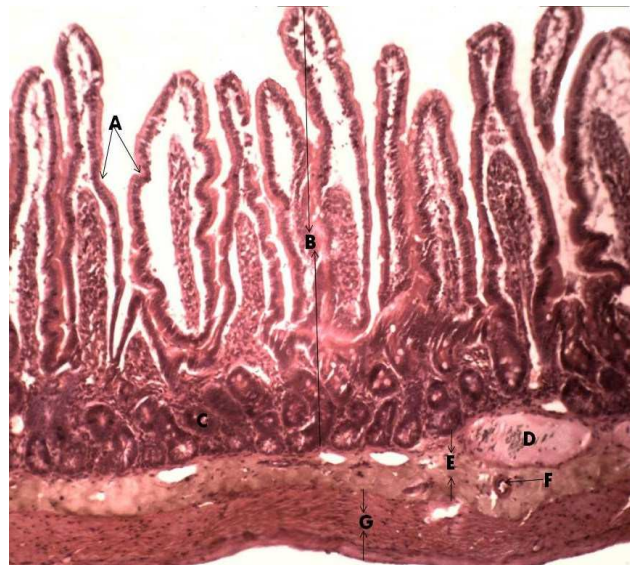

Plate II: Transverse section of the jejunum showing the mucosa fold (A), mucosa (B), intestinal glands (C), lymphatic nodule (D), submucosa (E), blood vessel (F) and tunica muscularis showing longitudinal muscles (G). H&E x40.

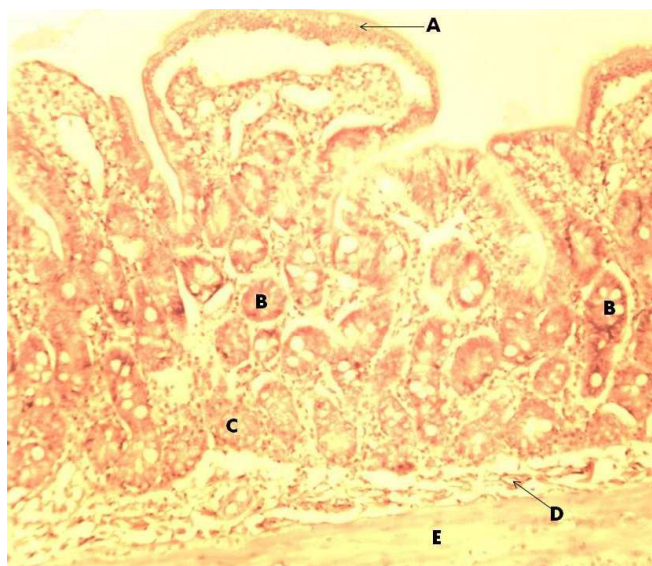


Plate III: Transverse section of the ileum showing the villi (A), intestinal glands (B), Payer's patches (C), blood vessel (D) and longitudinal muscle (E). H&E x100.

DISCUSSION

The small intestine was made up of the duodenum, jejunum and ileum. The small intestinal segments were observed to be longer than those of the large intestine. The jejunum was the longest segment of the GIT. This is in agreement with findings of [20] in squirrel. (27) however, observed that the colon was the longest segment in the Grass cutter. The feeding habit of the Grass cutter may be responsible for this. The histology of the small intestine of the AGR reveals similar structural pattern and indicates three segments, the duodenum, jejunum and ileum. These segments were modified and differentiated into the mucosa and submucosa folds. The shape of the villi was leaf-like in the duodenum and ridge-like in the jejunum. The Brunner's glands were found in the submucosa of the duodenum. The lamina propria of the jejunum had abundant intestinal glands (*crypts of Lieberkuhn*). [28] observed the location of the Brunner's glands to be in the first two-third part of the duodenum in the dog, cat and man. However, in the present study, the location of the Brunner's glands was not determined. Research on glands, villi and goblets cells have been widely documented [18, 29, 30, 31]. The absorption capacity of the small intestine is an important feature for the growth and survival of the AGR. In the present study the jejunum villi surface was observed to be more extensive compared to that of the duodenum and ileum, indicating that the absorptive capacity is highest in the jejunum compared to any other part of the small intestine and this confirms the report of [28].

CONCLUSION

The small intestine was observed to have three segments, the duodenum, jejunum and ileum. The jejunum was observed to be the longest segment of the small intestine with ileum being the shortest. The shape of the villi was leaf-like in the duodenum and ridge-like in the jejunum. The Brunner's glands were found in the submucosa of the duodenum. The lamina propria of the jejunum had abundant intestinal glands (*crypts of Lieberkuhn*).

REFERENCES

- [1] Delany, MJ and DCW Happold. Taxonomy of African Mammals. In *Ecology of African Mammals*, English Language Book Society 4th edition, **1979**, Pp.4.
- [2] Ajayi, SS. Domestication of the African Giant Rat (*Cricetomys gambianus* – Waterhouse). *Kwara State Printing and Publishing Corporation*. Ilorin, Nigeria, **1975**, Pp.1 – 44.
- [3] Dipeolu OO, OA Akinboade, and F Ogunji. *Bulletin of Animal Health and Production Africa*, **1981**, 29: 393 – 397.

- [4] Lariviere, M and A Buttner. *Helminthology Abstract*, **1961**, 31 : 437.
- [5] Lindow, M, The Landmines Sniffing rats of Mozambique. *Time Magazine*, 2001, Retrieve on **2008** – 06 – 08.
- [6] Ajayi, SS. The Biology and Domestication of the African Giant Rat (*Cricetomys gambianus* – Waterhouse). *PhD Thesis*, University of Ibadan, Ibadan, Nigeria, **1975**.
- [7] Oke, BO. Some Aspects of the Reproductive Biology of the Male African Giant Rat. (*Cricetomys gambianus* – Waterhouse) *Ph.D Thesis*, University of Ibadan, **1988**.
- [8] Oke, BO, and TA Aire. *Veterinarski Archiv*, **1989** 59: 267 – 274.
- [9] Oke, BO and TA Aire. *Veterinarski Archiv*, **1990**, 60: 207 – 212.
- [10] Oke, BO and TA Aire. *Veterinarski Archiv*, **1995**, 6: 125 – 135.
- [11] Ali, MN. Morphologic, Morphometric and Histologic Studies of the Female Reproductive Organs of the African Giant Rat (*Cricetomys gambianus*- Waterhouse). *M.Sc. Thesis*, Ahmadu Bello University, Zaria **2009**.
- [12] Nzalak, JO. Morphologic, Morphometric and Histologic Studies of cerebellum and Forebrain of the African Giant Rat (*Cricetomys gambianus*, Waterhouse). *M.sc Thesis*, Ahmadu Bello University, Zaria, **2002**.
- [13] Nzalak JO, JO Ayo, JS Neils, O Okpara, BI Onyeausi, A Ghaji and SA Ojo. *Tropical Veterinarian*, **2005**, vol. 23: (3&4) 87 – 92.
- [14] Nzalak J O, O Byanet., SO Salami, AD Umosen, SM Maidawa, MN Ali and J Imam. *Journal of Animal and Veterinary Advances*, **2008**, 7 (9): 1090-1092.
- [15] Ibe C. Anatomical Study of the Mesencephalic Tectum and Myelencephalon of the African Giant Rat (*Cricetomys gambianus* – waterhouse) *M.Sc. Thesis*, A.B.U. Zaria, **2010**.
- [16] Ewer R.F. The behavior of the African Giant rat (*Cricetomys gambianus* Waterhouse). 2. *Tierpsychology*, **1967**, 24: 6 – 79.
- [17] Getty R. Sissions and Grossman's. In *Gross Anatomy of Domestic Animals*: vols. I and II. 5th edition, **1975**, Pp 847-893 and 1232-1240.
- [18] Haroldy E. The Gastrointestinal tract. In *Clinical Anatomy. A Revision and Applied Anatomy for Clinical Students*, **1992**, 8th ed. Pp, 73 – 97.
- [19] Olds RJ and JA Olds. A Color Atlas of the Rat Disecting Guide. *Wolfe Publishing Ltd* 7th edition, **1991**, Pp. 45 – 50.
- [20] Nzalak JO, N Wanmi, and MO Samuel. *Journal of Veterinary Anatomy*, **2015**, Vol.8.No.2:59-68.
- [21] Devyn MS, C Rayetta, NGrast, CJ Theodosio, JT Clifford and MN Nanette. *Evolution and Development*, **2000**, 2(6): 348-359.
- [22] Ali MN, OByanet, SO Salami, J Imam, SM Maidawa, AD Umosen and JO Nzalak. *Journal of Scientific Research and Essay*, **2008**, 3 (10): 518 – 520.
- [23] Nzalak JO, BI Onyeausi, A.O Samuel, A.Voh and CS Ibe. *Journal of Veterinary Anatomy*, **2010a**, Vol. 3, No.2:55-56.
- [24] Nzalak JO, BI Onyeausi, SA Samuel, A Voh and CS Ibe, *Journal of Veterinary Anatomy*, **2011**, Vol. 4 No1:1-10.
- [25] Nzalak JO, BI Onyeausi, and SO Salami, *European Journal of Anatomy*, **2012**, 16(2):113-118.
- [26] Adeyemo O, and B Oke, *Tropical Veterinarian*, **1990**, 8:17 – 27.
- [27] Byanet O, JO Nzalak, SO Salami, IC Nwaogu and JA Bosha. *Veterinary Research*, **2008**, 2(2): 17-21.
- [28] Charlotte LO. Veterinary Histology VMED 7123, In on line lecture notes, **2004**, Pp1- 17.
- [29] Miller ME. Textbook of the Anatomy of the Dog. *McMiller Corp*. 1st edition, **1965**, Pp 1-4.
- [30] Dellmann H, and Brown EM. Histology of the Digestive System. In *Textbook of Veterinary Histology*. third edition. Lea and Febiger, **1987**, Pp. 229-247.
- [31] Timothy PJ. Comparative Gross Anatomical Studies of the Rabbit Digestive System. *DVM, ABU*, Student Project, **1990**.