



Scholars Research Library

Der Pharmacia Lettre, 2015, 7 (1):134-144  
(<http://scholarsresearchlibrary.com/archive.html>)



## ***Boswellia serrata* oleo- gum resin: A natural remedy for retrogradation of liver fibrosis in rats**

Hanaa H. Ahmed<sup>1\*</sup>, Nagla Z. El-Alfy<sup>2</sup>, Mahmmoud F. Mahmoud<sup>2</sup> and Shereen M.M. Yahya<sup>2</sup>

<sup>1</sup>Hormones Department, Medical Research Division, National Research Centre, Cairo, Egypt

<sup>2</sup>Biological and Geological Sciences Department, Faculty of Education, Ain Shams University, Cairo, Egypt

### **ABSTRACT**

*This study aimed to investigate the role of Boswellia serrata oleo – gum resin in ameliorating liver fibrosis induced by thioacetamide(TAA) in rats. Serum liver enzymes bilirubin , plasma fibrinogen,serum hepatocyte growth factor levels, hepatic reduced glutathione content were estimated . Also, hepatic NQO1 and BCL-2 gene expression levels were detected by semiquantitative RT-PCR. Moreover, histopathological investigation of liver tissue sections was carried out. TAA-challenged group showed significant elevation in the activity of serum liver enzymes, bilirubin and hepatocyte growth factor levels accompanied with significant reduction in plasma fibrinogen level and hepatic reduced glutathione content. Significant downregulation in hepatic NQO1 and BCL-2 gene expression levels were detected in TAA-challenged group relative to the negative control group. Histopathological investigation of liver tissue sections of rats in TAA-challenged group revealed many fibrotic features. Boswellia serrata -treated group showed significant depletion in serum liver enzymes activity, bilirubin and hepatocyte growth factor levels associated with significant elevation in plasma fibrinogen level and hepatic reduced glutathione content to near normal values. Moreover, this group showed dramatic upregulation in hepatic NQO1 and BCL-2 gene expression levels versus TAA-challenged group. Interestingly, treatment with Boswellia serrata resulted in marked improvement in the histological feature of liver tissue. In conclusion,this study provides a clear evidence for the promising role of Boswellia serrata gum extract in the retrogradation of liver fibrosis in the experimental model. Thes effect afforded by Boswellia serrata was likely attributable to its hepatoprotective activity, antioxidant capacity and antiapoptotic potential.*

**Keywords:** liver fibrosis, *Boswellia serrata*, antioxidant, apoptosis, Rats.

### **INTRODUCTION**

Liver is the main organ responsible for multitude of essential functions and plays an important role in the metabolism of foreign compounds entering the body. Human beings are exposed to these compounds through consumption of contaminated food or during exposure to chemical substances in the occupational environment. These foreign compounds produce variety of toxic manifestations particularly in the liver[1]. In Egypt, liver diseases are one of the most prominent killers specifically fibrosis, hepatitis C virus (HCV) and cirrhosis that alter the functions of the liver[2] .

Liver fibrosis is a wound healing process that results from chronic liver damage, such as alcohol abuse, chronic hepatitis, nonalcoholic steatohepatitis and overload of metal ions [3,4].Liver fibrosis is the final pathway for most chronic liver diseases and is the main reason for increased mortality in affected patients. Fibrotic tissue is characterized by loss of normal structure, replacement of blood vessels and other parenchymal structures by increasingly stable extracellular matrix (ECM), in which type I fibrillar collagen is the major component [5]. In the presence of hepatic injury, hepatic stellate cells (HSCs) become activated and transformed into proliferative myofibroblast-like cells, which are the major source of ECM. In general, liver fibrosis is an imbalance between the

synthesis and degradation of ECM and it is reversible before turning into cirrhosis, which is the irreversible end stage leading to liver failure [6]. Despite significant progress in our understanding of fibrogenesis, injury stimuli process, inflammation, HSC activation and ECM expression, there is still no standard treatment for liver fibrosis.

Thioacetamide (TAA, CH<sub>3</sub>-C(S) NH<sub>2</sub>) is a hepatotoxin and hepatocarcinogenic when administered in the experimental animals, and is widely used as a model of acute and chronic liver disease [7]. Briefly, TAA causes hepatocyte injury *via* biotransformation of TAA by cytochrome P450 2E1 (CYP2E1) enzymes located in the microsomes of liver cells into a highly reactive toxic intermediate known as thioacetamide sulphur dioxide (TASO<sub>2</sub>) [8]. This toxic metabolite induces hepatotoxicity in different grades of liver damage including fibrosis, nodular cirrhosis, production of pseudolobules, proliferation of hepatic cells, and necrosis of parenchyma cells in the experimental animals [9].

In traditional medicine, several plants and herbs have been used experimentally to treat liver disorders, including liver cirrhosis [10,11]. *Boswellia serrata* (Burseraceae), tree grows in tropical parts of Asia and Africa [12]. The oleo-gum-resin of the plant is known to possess a variety of activities such as antiarthritic, antiinflammatory, antitumour and anticarcinogenic effect [13, 14]. Pandey *et al.* [15] reported that the alcoholic extract of oleo-gum-resin of *Boswellia serrata* possesses hepatoprotective activity that may be due to the presence of acetyl- $\alpha$ -boswellic acid.

The present study was planned to investigate the efficacy of *Boswellia serrata* methylene chloride extract in management of liver fibrosis induced by thioacetamide in rats. In this study, we assessed the mechanism of action of *Boswellia serrata* gum extract in the retrogradation of liver fibrosis in the experimental model.

## MATERIALS AND METHODS

### I. Materials

#### *Plant material*

*Boswellia serrata* oleo-gum resin was purchased from local specialized market (seed, spices and medicinal plant company, Cairo, Egypt). *Boswellia serrata* taxonomical feature was kindly confirmed by Prof. Ibrahim El-Garf, professor of plant taxonomy, Botany Department, Faculty of Science, Cairo University, Egypt. Voucher specimen was kept in the museum of the Department of Pharmacognosy, Faculty of pharmacy, Cairo University, Egypt.

#### *Chemicals*

Thioacetamide (TAA) was purchased from Sigma Aldrich Chemical Co., (St. Louis, MO, USA) as pure crystals. It was dissolved in saline and freshly prepared prior to each injection. All other chemicals and solvents were of analytical grade and were obtained from commercial sources.

#### *Preparation of Boswellia serrata methylene chloride extracts (BSMC).*

*Boswellia serrata* oleo-gum resin extract was prepared by adding 4000 ml methylene chloride to 1 kg of *Boswellia serrata* oleo-gum resin powder and left for 72 hrs at room temperature. The extract was filtered using filter paper and the solvent was evaporated at 40 °C under reduced pressure using rotary evaporator (Heidolph, Germany) [16].

#### *Experimental Design*

For the present study, forty adult male albino rats of Wistar strain weighing 150-200 g were obtained from the Animal House Colony of the National Research Centre, Cairo, Egypt. The animals were housed in polypropylene cages in an environmentally controlled clean air room with a temperature of 25±1°C, an alternating 12h light/12h dark cycle, a relative humidity of 60 ± 5% and free access to tap water and a standard pellet diet. Rats were allowed to adapt to these conditions for 2 weeks before beginning the experimental protocol. The study was approved by the Ethics Committee for Medical Research, National Research Centre, Cairo, Egypt. After the acclimatization period, the animals were divided into four groups (10 rats / group) of equal average body weight and kept in well ventilated cages. They were labeled normally. Group (1): normal healthy animals served as negative control group, Group (2): positive control group (TAA group) in which the rats were intraperitoneally administered with TAA (dissolved in 0.9% normal saline) in a dose of 200 mg / kg b.wt. twice weekly according to Bruck *et al.* [17] for 7 consecutive weeks for induction of liver fibrosis, Group (3): *Boswellia serrata* control group in which the rats were treated orally with methylene chloride extract of *Boswellia serrata* oleo-gum resin (dissolved in distilled water) in a dose of 175mg / kg b.wt. according to Jyothi *et al.* [18] daily for 8 weeks. and Group (4): *Boswellia serrata* treated group in which the rats were treated orally with *Boswellia serrata* oleo-gum resin methylene chloride extract (dissolved in distilled water) in a dose of 175mg / kg b.wt. Daily for 8 weeks following the administration of TAA 200mg/kg b.wt for 7 weeks.

Body weight of rats was recorded once every week to monitor body weight change and to determine the doses for induction of liver fibrosis and treatment. After animal treatment was over, rats were fasted 12 hours, then they were anaesthetized with diethyl ether and blood samples were collected from the retroorbital venous plexus in centrifuge tubes. One portion of each blood sample was collected on EDTA for separation of plasma and the other portion was collected in a tube free from anticoagulant for separation of serum. Both plasma and serum samples were separated by centrifugation at 1800 xg for 15 minutes at 4 °C using cooling centrifuge. Aliquots of plasma and serum were frozen and stored at -20°C for further biochemical analysis.

After blood collection, the rats were sacrificed by cervical dislocation. Liver from each rat was quickly excised and thoroughly washed with isotonic saline and blotted dry. The whole liver of each rat in the different groups was divided into three portions; the first portion was snap-frozen directly in liquid nitrogen and stored at -80°C prior to RNA isolation for gene expression analysis, the second portion was homogenized in phosphate buffer (PH 7.4) to give 20% w/ v homogenate [19]. This homogenate was centrifuged at 1700 xg and 4°C for 10 min. and the supernatant was stored at -80°C until analysis. This supernatant (20 %) was used for the determination of hepatic reduced glutathione content. Whereas, the third portion of the liver was fixed in formal saline (10%) for histopathological examination.

## METHODS

### Biochemical analysis

Aspartate aminotransferase (AST) and alanine aminotransferase (ALT) activities in serum were assayed by kinetic method using Randox laboratories kits (UK) according to the methods recommended by the Committee on Enzymes of the Scandinavian Society for Clinical Chemistry and Clinical Physiology [20]. Serum alkaline phosphatase (ALP) activity was estimated by colorimetric method [21] using kit from Quimica Clinica Aplicada ( Amosta /Tarragona, Spain ). Serum bilirubin level was determined by colorimetric method according to Scherlock [22] using Randox laboratories kit (UK). Serum hepatocyte growth factor (HGF) was estimated by enzyme linked immunosorbent assay (ELISA) technique using a kit purchased from Glory Science Co., Ltd (USA), according to the manufacturer's instructions provided with HGF assay kit. Plasma fibrinogen was estimated by enzyme linked immunosorbent assay (ELISA) technique using fibrinogen ELISA kit purchased from Glory Science Co., Ltd (USA), according to the manufacturer's instructions provided with fibrinogen assay kit. Hepatic reduced glutathione content was quantified by colorimetric method according to Beutler *et al.* [23] using kit purchased from Bio-Diagnostic Co. ( Egypt).

### Gene expression analysis

100 mg of liver tissue was used for RNA extraction using PeqGold Trifast (Biotechnologie GmbH, USA) according to the manufacturer's instructions. Primer sequence for  $\beta$  actin gene is: Forward, ccttcctgggcatggagtcct; Reverse, ggagcaatgatcttgatcttc. Primer sequence for BCL-2 gene is: Forward, cctgttggaacacatcgcc; Reverse, aatcaaacagaggccgcatgc. Primer sequence for NQO1 is: Forward, aacgtcattctctggccaattc, Reverse, gccaatgctgtacaccagttga. Qiagen on step RT PCR kit (Qiagen Inc, USA) was used for RNA reverse transcription and subsequent amplification. PCR reaction was performed separately for  $\beta$  actin, BCL-2 and NQO1 by adding 2  $\mu$ g RNA to PCR mixture and making the reaction volume to 50  $\mu$ l. PCR mixture contained 2 mM tris Cl, 10 mM KCL, (NH)<sub>2</sub> SO<sub>4</sub>, 1.25 mM MgCl<sub>2</sub>, 0.1 mM dithiothreitol; PH 8.7, 0.4 mM dNTPs mixture, Qiagen one step RT PCR enzyme mix (contains Omniscript<sup>TM</sup> Reverse transcriptase, Sensiscript<sup>TM</sup> Reverse transcriptase and Hot star TaqR DNA polymerase), and 0.6  $\mu$ M of each specific primer. The reaction mixture was subjected to reverse transcription at 50°C for 30 minutes then to 35 cycles of PCR amplification as follows: denaturation at 94°C for 1 min, annealing at 55°C for 1 min and extension at 72°C for 1 min. The PCR products were separated on 1.5% agarose gel and visualized by gel documentation system. The gene expression levels were semiquantified using LabImage analysis (LabImage2.7.0, Kapelan GmbH) software.

### Histopathological examination

After fixation of liver tissues obtained from rats in the different studied groups in 10% formal saline for twenty four hours, washing was done in tap water. Then, serial dilutions of alcohol (methyl, ethyl and absolute ethyl) were used for dehydration. Specimens were cleared in xylene and embedded in paraffin at 56 degree in hot air oven for twenty four hours. Paraffin bees wax tissue blocks were prepared for sectioning at 4 microns thickness by slide microtome. The obtained tissue sections were collected on glass slides, deparaffinized, stained by hematoxylin and eosin stains. After that, examination was done through the light electric microscope [24].

### Statistical analysis

Data were analyzed using version 13 of computer based Statistical Package for Social Sciences (SPSS). Results are expressed as means  $\pm$  SD of three independent experiments. Statistical significance of difference was determined using analysis of variance (One way ANOVA). Further statistical analysis for post hoc comparisons was carried out using LSD test. A value of P <0.05 was defined as statistically significant.

## RESULTS

The data presented in **Table (1)** showed that administration of thioacetamide in rats significantly increases ( $P<0.05$ ) the activity of serum AST relative to the negative control group ( $95.6 \pm 2.7$  vs  $53.0 \pm 3.2$ ). *Boswellia serrata* control group showed insignificant change ( $P>0.05$ ) in serum AST activity in comparison with the negative control group ( $48.4 \pm 1.13$  vs  $53.0 \pm 3.2$ ). Significant decrease ( $P<0.05$ ) in serum AST activity was recorded in *Boswellia serrata* treated group versus the positive control (TAA group) ( $66.0 \pm 3.09$  vs  $95.6 \pm 2.7$ ). similar trend was noticed concerning serum ALT activity as significant increase ( $P<0.05$ ) in serum ALT activity was detected in the positive control group as compared to the negative control group ( $82.0 \pm 1.5$  vs  $39 \pm 3.1$ ). *Boswellia serrata* control group exhibited insignificant change ( $P>0.05$ ) in serum ALT activity with respect to the negative control group ( $38.4 \pm 1.1$  vs  $39.0 \pm 3.1$ ). Meanwhile, *Boswellia serrata* treated group displayed significant decrease ( $P<0.05$ ) in serum ALT activity as compared to the positive control group (TAA group) ( $58.4 \pm 1.1$  vs  $82.0 \pm 1.5$ ). In the same manner, significant increase ( $P<0.05$ ) in serum alkaline phosphatase (ALP) activity was obtained in the positive control group (TAA group) as compared to the negative control group ( $155.0 \pm 2.6$  vs  $106 \pm 0.7$ ). In contrast, *Boswellia serrata* control group displayed significant decrease ( $P<0.05$ ) in serum ALP activity relative to the negative control group ( $96.6 \pm 1.5$  vs  $106.0 \pm 0.7$ ). As well, *Boswellia serrata* treated group revealed significant decrease ( $P<0.05$ ) in serum ALP activity in comparison with the positive control (TAA group) ( $116.5 \pm 1.8$  vs  $155.0 \pm 2.6$ ). Similarly, serum bilirubin level was significantly elevated ( $P<0.05$ ) in the positive control group (TAA group) versus the negative control group ( $2.06 \pm 0.03$  vs  $0.81 \pm 0.02$ ). But, *Boswellia serrata* control group showed insignificant change ( $P>0.05$ ) in serum bilirubin level compared with the negative control group ( $0.79 \pm 0.02$  vs  $0.81 \pm 0.02$ ). Whereas, *Boswellia serrata* treated group revealed significant decrease ( $P<0.05$ ) in serum bilirubin level with respect to the positive control group (TAA group) ( $1.3 \pm 0.04$  vs  $2.06 \pm 0.03$ ) (Table 1).

**Table (1): Effect of *Boswellia serrata* oleo- gum resin extract on liver functions of rat model of liver fibrosis**

	Negative control Group	Positive control group (TAA group)	<i>Boswellia serrata</i> control group	<i>Boswellia serrata</i> treated group
AST(U/L)	$53.0 \pm 3.2$	$95.6 \pm 2.7^a$	$48.4 \pm 1.13$	$66.0 \pm 3.09^b$
ALT(U/L)	$39.0 \pm 3.1$	$82.0 \pm 1.5^a$	$38.4 \pm 1.1$	$58.4 \pm 1.1^b$
ALP(U/L)	$106.0 \pm 0.7$	$155.0 \pm 2.6^a$	$96.6 \pm 1.5^a$	$116.5 \pm 1.8^b$
Bilirubin(mg/dL)	$0.81 \pm 0.02$	$2.06 \pm 0.03^a$	$0.79 \pm 0.02$	$1.3 \pm 0.04^b$

Results are expressed as means  $\pm$  SD for 10 rats/ group.

"a" significant difference as compared to the negative control group at  $P<0.05$

"b" significant difference as compared to the positive control (TAA group) at  $P<0.05$

**Table (2): Effect of *Boswellia serrata* oleo-gum resin extract on hepatic glutathione content, plasma fibrinogen and serum hepatocyte growth factor levels in rat model of liver fibrosis**

	Negative control group	Positive control group (TAA group)	<i>Boswellia serrata</i> control group	<i>Boswellia serrata</i> treated group
Reduced glutathione (mg/g.tissue)	$12.8 \pm 0.8$	$7.5 \pm 0.9^a$	$13.07 \pm 0.75$	$9.9 \pm 0.34^b$
FBG ( $\mu$ g/mL)	$2116.6 \pm 28$	$1808 \pm 6.2^a$	$2115.0 \pm 12.9$	$2053.5 \pm 4.7^b$
HGF (ng/L)	$104.6 \pm 1.7$	$182.2 \pm 2.2^a$	$102.0 \pm 1.7$	$133.0 \pm 2.16^b$

Results are expressed as means  $\pm$  SD for 10 rats / group

FBG: Fibrinogen.

HGF: Hepatocyte growth factor

"a" significant difference as compared to the negative control group at  $P<0.05$

"b" significant difference as compared to the positive control (TAA group) at  $P<0.05$

As shown in Table (2), hepatic reduced glutathione (GSH) content of rats administered thioacetamide (positive control group) was significantly decreased ( $P<0.05$ ) as compared to the negative control group ( $7.5 \pm 0.9$  vs  $12.8 \pm 0.8$ ). *Boswellia serrata* control group showed insignificant change ( $P>0.05$ ) in hepatic GSH content relative to the negative control group ( $13.07 \pm 0.75$  vs  $12.8 \pm 0.8$ ). Meanwhile, *Boswellia serrata* treated group displayed significant increase ( $P<0.05$ ) in hepatic GSH content in comparison with the positive control group (TAA group) ( $9.9 \pm 0.34$  vs  $7.5 \pm 0.9$ ). Similarly plasma fibrinogen level in rats with liver fibrosis (positive control group) or TAA group revealed significant reduction ( $P<0.05$ ) versus the negative control group ( $1808 \pm 6.2$  vs  $2116.6 \pm 28$ ). But, *Boswellia serrata* control group showed insignificant change ( $P<0.05$ ) in plasma fibrinogen level compared with the negative control group ( $2115 \pm 12.9$  vs  $2116.6 \pm 28$ ). However, *Boswellia serrata* treated group revealed significant elevation ( $P<0.05$ ) in plasma fibrinogen level as compared to the positive control group or (TAA group) ( $2053.5 \pm 4.7$  vs  $1808 \pm 6.2$ ). Also, the data illustrated in Table (2) revealed significant increase ( $P<0.05$ ) in serum HGF level was demonstrated in rat with liver fibrosis (positive control group or TAA group) as compared to the



negative control group ( $182.2 \pm 2.2$  vs  $104.6 \pm 1.7$ ). *Boswellia serrata* control group showed insignificant change ( $P < 0.05$ ) in serum HGF level in comparison with the negative control group ( $102.0 \pm 1.7$  vs  $104.6 \pm 1.7$ ). Meanwhile, *Boswellia serrata* treated group exhibited significant decrease ( $P < 0.05$ ) in serum HGF level relative to the positive control group (TAA group) ( $133.0 \pm 2.16$  vs  $182.2 \pm 2.2$ ). (Table 2).

Data depicted in Table (3) and Fig (1) revealed that, hepatic NQO1 gene expression level is significantly reduced ( $P < 0.05$ ) in the liver of rats with liver fibrosis (positive control group or TAA group) compared with the negative control group ( $0.21 \pm 0.01$  vs  $0.87 \pm 0.01$ ). Meanwhile *Boswellia serrata* control group showed significant increase ( $P < 0.05$ ) in hepatic NQO1 gene expression level relative to the negative control group ( $1.02 \pm 0.02$  vs  $0.87 \pm 0.01$ ). Similarly, significant increase ( $P < 0.05$ ) in hepatic NQO1 was detected in *Boswellia serrata* treated group with respect to the positive control group (TAA group) ( $0.62 \pm 0.03$  vs  $0.21 \pm 0.01$ ). In the same manner, hepatic BCL-2 gene expression level of the positive control (TAA group) showed significant reduction ( $P < 0.05$ ) as compared to the negative control group ( $0.32 \pm 0.01$  vs  $0.69 \pm 0.01$ ). But hepatic BCL-2 gene expression level in *Boswellia serrata* control group did not show any significant change ( $P > 0.05$ ) relative to the negative control group ( $0.62 \pm 0.03$  vs  $0.69 \pm 0.01$ ). Meanwhile, hepatic BCL-2 gene expression level revealed significant elevation ( $P < 0.05$ ) in *Boswellia serrata* treated group in comparison with the positive control group (TAA group) ( $0.45 \pm 0.22$  vs  $0.32 \pm 0.01$ ) (Table 3) and Fig(1).

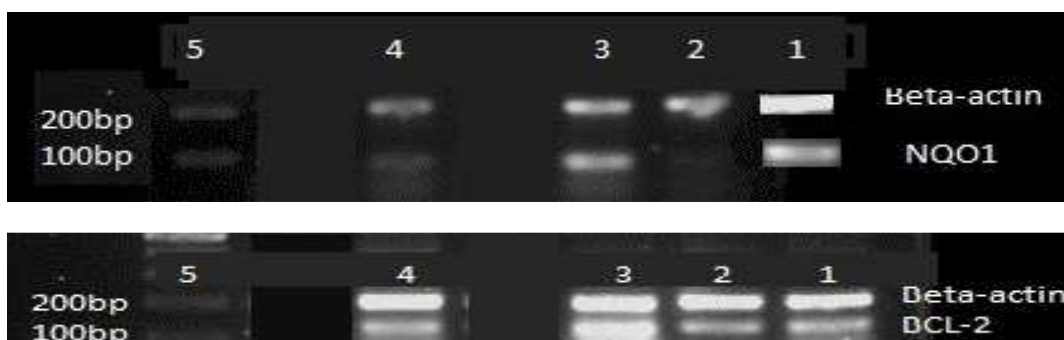
**Table (3): Effect of *Boswellia serrata* gum methylene chloride extract on hepatic gene expression levels of NQO1 and BCL-2 in rat model of liver fibrosis**

	Negative control group	Positive control group (TAA group)	<i>Boswellia serrata</i> control group	<i>Boswellia serrata</i> treated group
NQO1	$0.87 \pm 0.01$	$0.21 \pm 0.01^a$	$1.02 \pm 0.02^a$	$0.62 \pm 0.03^b$
BCL-2	$0.69 \pm 0.01$	$0.32 \pm 0.01^a$	$0.62 \pm 0.03$	$0.45 \pm 0.22^b$

Results are expressed as means  $\pm$  SD for 10 rats / group.

"a" significant difference as compared to the negative control group at  $P < 0.05$

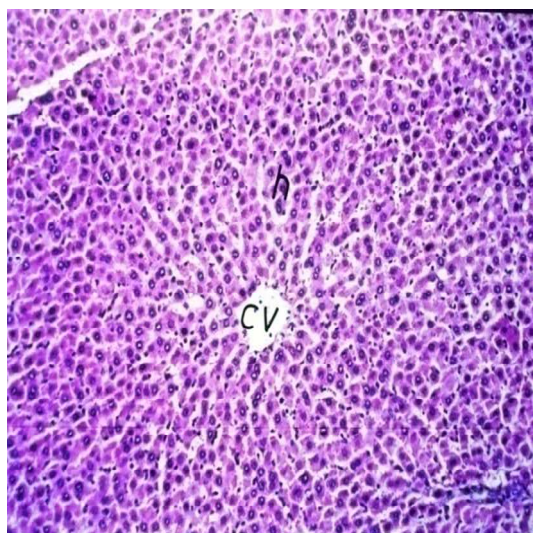
"b" significant difference as compared to the positive control (TAA group) at  $P < 0.05$



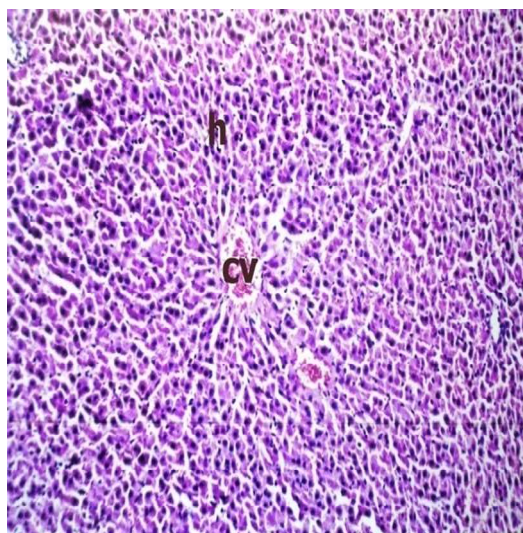
**Fig (1): RT-PCR product of hepatic NQO1, BCL-2 and  $\beta$ -actin genes expression in the negative control, positive control *Boswellia serrata* control and *Boswellia serrata* treated rats. Lane 1 represents negative control, lane 2 represents positive control, lane 3 represents *Boswellia serrata* control, lane 4 represents *Boswellia serrata* treated group and lane 5 represents DNA marker**

### Histopathological findings

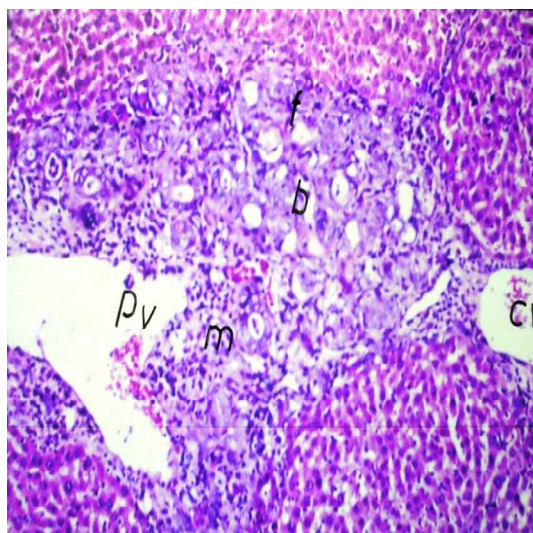
Histological examination of liver tissue sections of rats in the negative control group showed no histopathological alteration and the normal histological structure of the central vein and surrounding hepatocytes were noticed (Fig 2). Histological examination of liver tissue sections of rats in *Boswellia serrata* control group showed no evidence of histopathological changes and the normal histological structure of the central vein and surrounding hepatocytes were recorded (Fig.3). Histological investigation of liver tissue sections of rats in the positive control group revealed multiple number of newly formed bile ductules with inflammatory cells infiltration and fibroblastic cells proliferation in the portal area with congestion in the central and portal veins. The hepatic parenchyma was divided into nodules by the proliferating fibroblasts and inflammatory cells infiltration (Fig. 4). Histological investigation of liver tissue sections of rats in *Boswellia serrata* treated group showed Inflammatory cells infiltration in few manner in the portal area as well as between the hepatocytes (Fig.5).



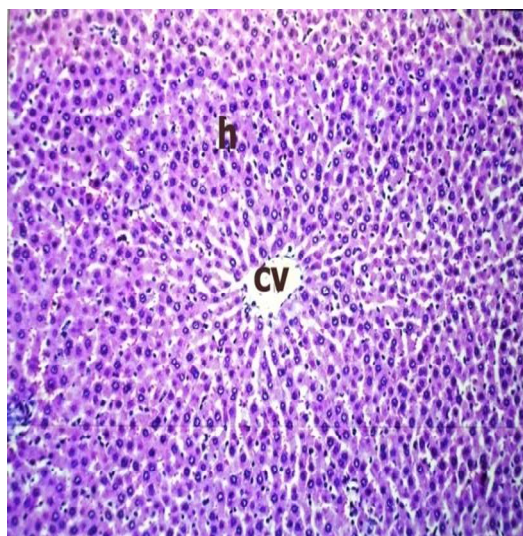
**Fig(2):** Photomicrograph of liver tissue section of rats represented the negative control group showing normal histological structure(H&Ex40).



**Fig (3):** Photomicrograph of liver tissue section of rat in *Boswellia serrata* control group showing normal histological structure (H&Ex40).



**Fig (4):** Photomicrograph of liver tissue section of rat represented the positive control group showing multiple number of newly formed bile ducts (b) with inflammatory cells infiltration (m) and fibroblastic cell proliferation (f) in between as well as sever congestion in central (cv) and portal vein (pv) (H&Ex40).



**Fig(5):** Photomicrograph of liver tissue section of rat in *Boswellia serrata* treated group showing few inflammatory cells infiltration (m) in the portal area and in between the hepatocytes (H&Ex40).

## DISCUSSION

Liver fibrosis has become a serious health problem because of the wider use of prescribed medications with adverse reactions in modern life of today or the drug misuse. consequently, the current research has targeted on finding new



therapeutic alternatives and analyzing their mechanism to get rid of the signaling routes and reduce the loss induced on the liver[25]. Beyond the techniques with artificial pharmacology, the search also chases alternative techniques that depend on natural products. In particular, it targets those plants with known medical history or confirmed prospective of positive results against the illnesses of the liver or other body parts[26]. To aid these initiatives, in this study, we analyzed the mechanism of methylene chloride extract of *Boswellia serrata* oleo- gum resin.

Thioacetamide (TAA) is a well-established agent for induction of liver fibrosis in the experimental animal model[27]. TAA induces hepatocyte damage via its metabolite, TASO<sub>2</sub>, which damages the macromolecules of hepatocytes causing damage of DNA molecules, oxidation of protein molecules, and peroxidation of the cell membrane biomolecules[28,29]. When hepatic cell membrane is damaged, the enzymes ALT, AST and ALP which are normally located in the cytosol, leaked into circulation from hepatocytes[30]. As a result, the activity of these enzymes (ALT, AST and ALP) is increased in serum. Therefore, the increased activity of serum ALT, AST and ALP is considered as the most frequent indicator for liver diseases. In this study, administration of TAA in rats elicited significant increase in the activity of serum ALT, AST and ALP as well as serum bilirubin level. These findings are in accordance with those of the earlier studies which demonstrated similar biochemical changes [31]. Thioacetamide causes oxidative stress and enhances free radical-mediated damage to proteins, lipids and deoxyribonucleic acid (DNA)[32-35]. Such oxidative stress was indicated by the occurrence of the hepatocellular injury leading to cell necrosis and discharge of the contents of the hepatocytes into the blood stream. It has been reported that serum ALT and AST activities are very sensitive indicators for necrotic lesions within the liver because their ease liberation from the hepatocyte cytoplasm into the blood stream[27] as a result of membrane lipid peroxidation[36]. TAA is known to cause changes in cell membrane permeability by its metabolite TASO<sub>2</sub> [37] and the elevated serum enzymes are indicative of cellular leakage and loss of functional integrity of the liver [38]. The elevated serum level of bilirubin in TAA administered group in the current study comes in line with the previous results of El-Kott and Owayss[39]. The increased bilirubin level in serum indicates the diffused harm to the liver with more and more liver tissue damage [40]. Thus, the elevated serum values of each of ALP and bilirubin in TAA administered rats clearly indicates the liver injury in concomitant with liver dysfunction due to TAA intoxication. As the increased serum ALP activity and bilirubin level are also related to the function of hepatic cells[41].

Interestingly, treatment with *Boswellia serrata* oleo- gum resin extract for 8 weeks effectively reversed the significant elevation in serum ALT, AST, ALP activities and bilirubin level in TAA administered rats. These findings are in agreement with those of Ibrahim *et al.* [42] who found that administration of *Boswellia serrata* gum extract significantly reduces the damaging impact of paracetamol on the liver. The positive effect of *Boswellia serrata* on liver enzymes is possibly ascribed to the inhibitory impact of *Boswellia serrata* extracts on the synthesis of 5 LOX (Lipo oxygenase enzyme) which is primarily responsible for injury and inflammation of hepatocytes. Moreover, Ibrahim *et al.* [42] stated that *Boswellia serrata* extracts reduces the damaging insult of TAA on hepatocytes membrane. Thus, *Boswellia serrata* possesses anti-inflammatory and hepatoprotective activity. Such activity of *Boswellia serrata* could be attributed to its content of boswellic acids, the main active constituents of gum resin of *Boswellia serrata*. Boswellic acids have been used for the treatment of inflammatory diseases for many years in the different countries of the east[43]. More in detail, Ammon *et al.*[44] stated that Acetyl-boswellic acids exhibit anti-inflammatory behavior by inhibiting leukotriene synthesis[44]. This effect is mediated through the inhibition of the activity of the enzyme 5LOX through a non-redox reaction. Concerning the hepatoprotective effect of *Boswellia serrata*, it has been speculated that *Boswellia serrata* may reduce the production of nitric oxide in the hepatocytes and this may be responsible for its hepatoprotective action[45]. Supporting evidences indicated the prophylactic and curative efficacy of *Boswellia serrata* in maintaining the integrity and functional status of hepatocytes[42,46]. The underlying mechanism for this effect is that in rat liver microsomes and hepatocytes, 11-keto- $\beta$ -boswellic acid undergoes extensive phase I metabolism. Oxidation of 11-keto- $\beta$ -boswellic acid to its hydroxylated metabolites is the principal metabolic route. *In vitro*, 11-keto- $\beta$ -boswellic acid yielded metabolic profiles similar to those obtained *in vivo* in rat plasma and liver[47]. *Boswellia serrata* or boswellia acids, exhibit potent anti-inflammatory properties demonstrated both *in vivo* and *in vitro*. Triterpenes in boswellic acid reduce the synthesis of leukotrienes in intact neutrophils by inhibiting 5-lipoxygenase, the key enzyme involved in biosynthesis of leukotrienes, which mediate inflammation. Leukotrienes form via the lipoxygenase pathway, subsequent to the enzymatic oxidation of arachidonic acid. Leukotrienes incite chemotaxis, chemokinesis, superoxide radical formation and phagocytic expulsion of lysosomal enzymes[48].

Superoxide radicals are reactive oxygen species ROS was found to control tightly with mitochondrial signaling the cellular homeostasis by regulating fundamental cell death and cell survival processes like apoptosis and autophagy[49]. Additionally ROS production enhances mitochondrial depolarization and hence affecting transmembrane potential[50]. Consequently boswellic acid can enhance cell survival by reducing ROS production

and consequently preserving mitochondrial transmembrane potential to protect the cell against cell death signals. Therefore, it could prevent the leakage of liver enzymes into serum and restore the liver functions.

It is well known that the toxicity of TAA results from its bioactivation in the liver to its reactive metabolites, causing the production of ROS responsible for oxidative stress [51]. This is followed by glutathione depletion, reduction of SH-thiol groups and oxidation of cell macromolecules, including lipids [52].

The present study showed significant depletion in hepatic glutathione content in TAA administered rats. This finding coincides with that of Sanz *et al.* [53] and Diez-fernandez *et al.* [54]. In tissues, glutathione occurs in a reduced (GSH) and oxidized form (GSSG). More than 99% of the total glutathione occurs as GSH [55, 56]. Glutathione plays a key role in detoxification of ROS and reactive electrophilic compounds [57, 58]. TAA is known to induce hepatocyte damage following its metabolism to TAAO<sub>2</sub>, via a critical pathway involving cytochrome P450-mediated biotransformation [51]. These metabolites are highly reactive and thus lead to the denaturation of cellular biomolecules such as lipids, resulting in lipid peroxidation [59]. The mechanisms that contribute to the occurrence of lipid peroxidation not only include oxygen free radical generation, but also include alterations in the cellular antioxidant defense system in association with a decline in the intracellular free radical scavengers [60]. Another additional mechanism for the decline of hepatic reduced glutathione content by TAA in our study may be related to the inhibition of its regenerating enzyme, glutathione reductase (GSH-Rx), by TAA administration [61]. Reduced glutathione (GSH) is regenerated from oxidized glutathione (GSSG) and NADPH in a reaction catalyzed by GSH-Rx. NADPH, in turn, is generated via the hexose monophosphate shunt by a reaction catalyzed by glucose 6 phosphate dehydrogenase (G6PD) [62]. Therefore, the deficiency of GSH content in the liver seems to be attributed, in part, to a deficiency in G6PDH which is considered a house keeping enzyme that catalyses the first step in the pentose phosphate pathway to produce NADPH, that is necessary for the reduction of GSSG to GSH [63]. On the other side, treatment of TAA-challenged rats with *Boswellia serrata* induced a significant elevation in hepatic reduced glutathione content. This result is in conformity with the previous study of Hartmann *et al.* [64] who stated that the treatment with *Boswellia serrata* produces significant increase in the activity of glutathione in the experimental model of colitis. Accumulated evidences have suggested that essential oils (monoterpenes, sesquiterpenes and phenolic compounds) of *Boswellia serrata* are the important sources of natural antioxidants. These essential oils might be helpful in preventing the progression of many diseases induced by oxidative stress [65]. *In vitro* study on the methanolic and aqueous extract of *Boswellia serrata* revealed that it contains high amount of total flavonoids and total phenolics compounds that significantly inhibit the nitrite formation, superoxide free radical generation, scavenge DPPH and spare glutathione [66]. In a series of experiments, it was found that relatively low concentrations of flavonoids stimulated transcription of a critical gene for GSH synthesis in the cells [67].

From another point of view, boswellic acids (BAs) content of *Boswellia serrata* gum resin may be responsible for restoring hepatic glutathione content in the treated rats. BAs possess anti-fibrotic activity as they are potent inhibitors of TGF- $\beta$ 1 signaling *in vivo* [68]. TGF- $\beta$ 1 may be a key growth factor in the initiation of fibrosis [69]. TGF- $\beta$ 1 down regulates the mRNA synthesis of glutamate cysteine ligase, the rate-limiting enzyme in the production of the antioxidant molecule glutathione [70]. Glutathione synthesis is decreased in TGF- $\beta$  over expressing mice [71]. Therefore the down-regulation of TGF- $\beta$ 1 by BAs is responsible for the up-regulation of glutathione content of the liver.

Fibrinogen is a glycoprotein of molecular weight approximately 340,000 daltons, present in the plasma at a concentration in the range of 2–4 g/l. It is synthesized in the liver (1.7–5 gm/day), and by the megakaryocytes [72]. In this study, Plasma fibrinogen levels showed significant decrease in TAA-challenged group in comparison with the negative control group. This finding is in agreement with Chang *et al.* [73]. Aster [74] reported that low level of fibrinogen among other coagulation proteins in fibrosis is classically ascribed to insufficient hepatic synthesis. In addition, the decreased fibrinogen level in liver fibrosis may occur due to the increased fibrinogen degradation products.

Plasma fibrinogen level was significantly increased in *Boswellia serrata* treated group versus the positive control group (TAA group). In 2010, Mallik *et al.* [75] formulated a cream using oleo-gum-resins of *Boswellia serrata* and applied the cream topically on the excision wound surface as single dose at different percentages. Results of the application of this formulation indicated that *Boswellia serrata* influences various phases of wound healing like fibroplasias, collagen synthesis and wound contraction, decreases surface area and increases the tensile strength of the wound as well resulting in faster healing [75]. *Boswellia serrata* has been shown to reduce platelet aggregation and increase fibrinogen. Modes of action apparently involve eicosanoid modulation, inhibition of enzymes as well as inflammatory mediators and antioxidant activity [76, 77]. In particular, the antioxidant and hepatoprotective



activity of *Boswellia serrata* active ingredients is responsible for restoring liver functions[42,46] with consequent production of fibrinogen.

Hepatocyte growth factor (HGF), also known as SF (scatter factor) is a pleiotropic cytokine involved in many complex biological processes, from embryogenesis and tissue regeneration to tumour growth, metastasis and angiogenesis[78]. Serum hepatocyte growth factor (HGF) was significantly increased in rats administered TAA relative to the negative control ones. HGF play an important role in liver regeneration as an endocrine or paracrine factor. In the liver, HGF is synthesized by non parenchymal cells and targets both parenchymal hepatocytes and bile duct epithelial cells [79]. The signal-transducing receptor for HGF is the c-met protooncogene product of transmembrane tyrosine kinase[80]. Matsumoto and Nakamura [79] reported that HGF mRNA and HGF activity are increased in the liver of rats after various liver injuries. Also, HGF level is increased markedly in mouse liver after various liver injuries such as hepatitis, ischemia, physical crush and partial hepatectomy [81]. HGF promotes hepatic survival by stimulating liver regeneration and providing hepatoprotection in various models of liver injury. It has been proven that HGF, transforming growth factor-  $\alpha$  (TGF- $\alpha$ ) and epidermal growth factor (EGF) are the main growth factors secreted after hepatic injury. HGF is the most potent mitogen for mature hepatocytes and acts as a hepatotropic factor. Treatment of TAA-challenged rats with *Boswellia serrata* produced significant reduction in serum HGF level as compared to the positive control rats (TAA group).

A protection afforded by *Boswellia serrata* against the increased HGF serum level was likely attributable to its antioxidant [76], anti-inflammatory<sup>[44]</sup> and hepatoprotective effects. These properties of *Boswellia serrata* could improve the structural and functional integrity of the liver leading to the reduced HGF protection.

NADPH quinone oxidoreductase 1 (NQO1) is the major phase- II detoxification enzyme controlled by *Nrf2* which is an important transcription factor that regulates antioxidative stress reactions [82]. In this study, TAA administered group exhibited significant reduction in hepatic NQO1 gene expression level relative to the negative control group. Demirel et al. [83] stated that TAA administration in rats lowered *Nrf2* gene expression in the liver. And hence, the significant reduction of NQO1 gene expression in TAA- administered rats could be attributed to the lowering effect of TAA on *Nrf2* gene expression. Interestingly, significant elevation in hepatic NQO1 gene expression level was detected in *Boswellia serrata* treated group in comparison with the positive control group (TAA group). This apparent effect of *Boswellia serrata* on amelioration of NQO1 gene expression level could be due to the antioxidant activity of its active constituents as reported by Srivastava et al.[76]. This potent effect of *Boswellia serrata* helps in counteraction of oxidative stress elicited by TAA and in turn restoration of NQO1 gene expression level in the liver of the treated rats.

BCL-2 gene is the founding member of the BCL-2 family of proteins that regulate cell death (apoptosis)[84]. Upregulated apoptosis of hepatocytes is increasingly viewed as a nexus between liver injury and fibrosis. In our study, TAA administration induced, significant decrease in BCL-2 gene expression level in the liver relative to the negative control group. Cytotoxic drugs and cellular stress activate the intrinsic mitochondrial apoptotic pathway [85] so that the inhibitors of BCL-2 activate caspase-3 initiating apoptosis, whereas inducers of BCL-2 induce necrosis of cells [86]. In consistent with our results, TAA has been reported to cause upregulation of Bax protein and downregulation of the antiapoptotic protein BCL-2 and its translocation into the mitochondria, causing apoptosis[87].

*Boswellia serrata* treated group displayed significant up regulation in BCL-2 gene expression level in the liver of TAA administered rats versus positive control rats (TAA group). This finding highlights the potential role of *Boswellia serrata* in retarding TAA-induced apoptosis. Intracellular ROS loading directly entail the depletion of intrinsic antioxidant potentials and the activation of the transduction pathways leading to apoptosis [88, 89].

This fact speaks for the importance of the antioxidant mechanism in the therapeutic action of *Boswellia serrata* [76] against liver fibrosis associated with hepatic apoptosis. As the downregulation of ROS loading of hepatocytes and the activation of the antioxidant defense system may account for the inhibition of apoptosis with consequent upregulation of hepatic BCL-2 gene expression level.

In the histopathological investigations of this study, numerous macronodules were seen on the surface of fibrotic livers of rats administered TAA for 6 consecutive weeks (positive control group). Moreover, the liver tissue section showed portal fibrosis and expansion of connective tissue (portal and peripheral fibrosis). Furthermore, multiple numbers of newly formed bile ductules with inflammatory cells infiltration and fibroblastic cells proliferation were detected in the portal area accompanied with a congestion in the central and portal veins. The hepatic parenchyma was divided into nodules by the proliferating fibroblasts and inflammatory cells infiltration. Similar findings have been demonstrated by Nozu *et al.*[27] who found that TAA administration produces portal fibrosis consisting of

expansion of the connective tissue of the portal area. Also chronic poisoning with TAA by intraperitoneal injection induced changes in the periportal collagen deposit[90]. Moreover, progressive changes in the liver, such as cellular necrosis as well as hepatic fibrosis with the formation of pseudo-lobules due to TAA intoxication have been reported by Zsigmond et al .[91]. The present histopathological examination of rat liver tissue from *Boswellia serrata* control group showing normal liver architecture with no evidence of pathological alteration. This was probably due to the hepatoprotective activity of the plant extract.

The current histopathological findings indicated that *Boswellia serrata* restores the structural organization of the liver. *Boswellia serrata* treatment daily for 8 weeks after 6 weeks of TAA administration ameliorated liver tissue damage to great extent as documented by the presence of few inflammatory cells infiltration which was observed in few manner in the portal area as well as between the hepatocytes This indicates its ability to maintain the structural integrity of hepatocytic cell membrane .This effect of *Boswellia serrata* is considered as an index of its hepatoprotective potential.

**In conclusion**, our data provided a clear evidence for the potent antifibrotic efficacy of *Boswellia serrata* gum extract in the experimental model of liver fibrosis. *Boswellia serrata* offered multimechanistic approaches for regression of liver fibrosis including hepatoprotective activity, antioxidant capacity and antiapoptotic potential. These findings would encourage further studies on the pharmacological significance of using plant extracts as alternative medicines for treating liver diseases.

## REFERENCES

- [1] M. Athar, ZS Hussain , N. Hassan In: Rana SVS, Taketa K, (Ed.). Liver and Environmental Xenobiotics. Narosa Publishing House ,New Delhi. **1997**.
- [2] M M K Habib , F Mohamed, LS Abdel-Aziz , M Magder , F Abdel-Hamid, S Gamil , N N Madkour, *Hepatol.* **2001**,33, 248-253.
- [3] R Raghow, J. Faseb **1994**, 8,823–31.
- [4] KT Weber, *Circulation*.**1997**, 96,4065–82.
- [5] J Varga, DA Brenner, SH. Phan Fibrosis Research. Humana Press Inc. Totowa, New Jersey, **2005**.
- [6] SL Friedman, *J Hepatol.* **2003**,38,38–53.
- [7] S K Ramaiah, U Apte, H M Mehendale, *Int J Toxicol.* **2000**,19,413-424.
- [8] KH Kim, JH Bae, SW Cha, SS Han, KH Park, TC Jeong, *Toxicology Letters*.**2000**,114,225–235.
- [9] S Sadasivan, PG Latha, JM Sasikumar, S Rajashekar, *Journal of Ethnopharmacology*. **2006**, 106,245–249.
- [10] M A Alshawsh, M A Abdulla, S Ismail, Z A Amin *Evid Based Complement Alternat Med.* **2011**,2011:1-6.
- [11] F A Kadir, F Othman, M A Abdulla, F Hussan, *Indian J Pharmacol*.**2011**,43,64.
- [12] CK Kokate , Pharmacognosy, Nirali Prakashan, New Delhi.**1998**, 209.
- [13] GB Singh, CK Atal, *Agents Actions*.**1986**, 18,407- 412.
- [14] M T Huang, V Badmaev, Y Ding, Y Liu , J G Xie, CT Ho, *Biofactors*. **2000**,13,225-230.
- [15] R S Pandey, B K Singh Y B Tripathi, *Indian J. Exp. Biol.* **2005**,43, 509-516.
- [16] ON Pozharitskaya, SA Ivanova, AN Shikov, V G Makarov, *J Sep Sci.* **2006**,29,2245-2250.
- [17] R Bruck, H Shirin, H Aeed, Z Matas, A Hochman, M Pires, *J.Hepatol*.**2001**,35, 457-64.
- [18] Y Jyothi, J Kamath, M Asad , *J. Pharm. Sci.***2006**,19,125-129.
- [19] C C Lin, Y F Hsu, T C Lin, F L Hsu, H Y Hsu, *J.pharm.pharmacol*.**1998**, 50:789-794.
- [20] The Committee on Enzymes of the Scandinavian Society for Clinical chemistry and clinical physiology , *Scand.J.Clin. Lab. Invest.* **1974**,33,291-306.
- [21] O A Bessey, O H Lowry, M J Brock, *J.Biol.Chem.* **1946**, 164,321-329.
- [22] S Scherlock, In: Liver Disease. Churchill, London. **1951**,204.
- [23] E Beutler, O Duron , M B Kelly, *J.Lab Clin.Med.***1963**,61,882-8.
- [24] J D Bancroft, A Stevens, D R Turner, Theory and Practice of Histological Techniques., Churchill Livingstone, New York, London, San Francisco, Tokyo; **1996**, 4<sup>th</sup>ed.
- [25] A K Daly , P T Donaldson, P Bhatnagar et al, *Nature Genetics*.**2009**,41,816-819.
- [26] D Khanna, G Sethi , S Ahn, et al, Current Opinion in pharmacology.**2007**,7,344-351.
- [27] F Nozu, N Takeyama, T Tanaka , *Hepatology*.**1992**,15,1099-1100.
- [28] J Chilakapati , M C Korrapat, R A Hill, A Warbritton , J R Latendresse, *Toxicology*.**2007**,230,105-116.
- [29] V B Djordjevic, *International Review of Cytology*.**2004**,237,57-89.
- [30] W R Kirchain, M A Gill. In: JT Dipiro, RL Talbert, GC Yee, GR Matzke, BG Wells (ed), pharmacotherapy, Connecticut: Appleton and Lang.**1997**, 801-814, (3rd ed)
- [31] D D Cintia, R Graziella, B Silvia, M luise, G LG Javier, *Toxicologic Pathology*. **2011**, 39, 949-957.
- [32] S C Lu, Z Z Huang, H Yang, H Tsukamoto, *Toxicol Appl Pharmacol*.**1999**,159, 161–8.
- [33] R Bruck, H Aeed, Y Avni, H Shirin , Z Matas, M Shahmurov, I Avinoach, *J Hepatol*.**2004**, 40, 86–93.

- [34] I Tunez, M C Munoz , M A Villavicencio, F J Medina, E P de Prado, I Espejo, *Pharmacol Res.* **2005**, 52, 223–8.
- [35] M S Uskokovic, M Milenkovic, A Topic , *J Pharm Pharm Sci.* **2007**,10 340–9.
- [36] JA Wendel, S Feuerstein, K H Konz, *Biochem Pharmacol.* **1979**, 28,2051-2055.
- [37] R A Neal, J Halpert, *Ann Rev Pharmacol Toxi.* **1982**, 22,321-9.
- [38] R B Drotman, G T Lawhorn, *Drug Chem Toxicol.* **1978**, 1,163-171.
- [39] A F El-Kott , A A Owayss, *Am J Pharmacol Toxicol.* **2008**,3,402-408.
- [40] S S Alkiyumi, MM Abdullah, AS Alrashdi, *Molecules.* **2012**, 17, 6146-6155.
- [41] J Y P Liu, C Madhu , C D Klaassen,*J Pharmacol Exp THER.***1993**,266,1607-1613.
- [42] M Ibrahim, K Z Uddin, M.L Narasu, *Int. J. Drug Formulation Res.* **2011**,2,179-199
- [43] J Liu, A Nilsson, S Oredsson, V Badmaev , R Duan, *Carcinogenesis.* **2002**,10, 1107-3756.
- [44] H Ammon, H Safayi , T Mack , J Sabieraj, *Journal of Ethnopharmacology* .**1993**,38 113–9.
- [45] B Gayathri , N Manjula, K S Vinaykumar, B S Lakshmi, *Int. Immunopharmacol.* **2007**, 7:,473-482
- [46] Y J, Kamath J, Asad M, *Pak J Pharm Sci.***2006**, 19 , 129–33.
- [47] P Krüger, R Daneshfar, P Gunter , *Drug Metabolism and Disposition.* **2008** 36, 1135-1142.
- [48] S Roy, S Khanna, AV Krishnaraja, *Antioxidants and Redox signaling.* **2006**,8,653-660.
- [49] S Marchi, C Giorgi, J Suski, B Angoletto, *Journal of signal transduction.***2012**, 10,329,35.
- [50] SJ Cherra , RK Dagda , A Tandon , CT Chu , *Autophagy.***2009**,5,1213-4.
- [51] H Okuyama, H Nakamura, Y Shimahara, S Araya, *Hepatology.* **2003**,37, 1015–1025.
- [52] P S kova, O K era, H Lotkova, T Roušar, *Toxicology in Vitro.* **2010**,24 ,2097–2103.
- [53] N Sanz, D Fernandez, D Andres, *Biochimica et Biophysica Acta,* **2002**,1587,12–20.
- [54] C Diez-Fernandez, N Sanz , *Biochemical pharmacology.* **1996**, 51, 1159-1163.
- [55] A Meister, *The Journal of Biological Chemistry.***1988**, 263, 17205–17208.
- [56] D A Dickinson, H J Forman, *Cell. Biochem. Pharmacol.* **2002**, 64,1019–1026.
- [57] D Han, R Canali , D Rettori , *Molecular Pharmacology* . **2003**,64, 1136–1144.
- [58] L D Deleve, N Kaplowitz, *Pharmacology and Therapeutics* .**1991**, 52,287–305.
- [59] W Cheng Haung ,C Yannjan , L Tsung Hsing , C Yi-Shen , J Bruno, H Kuo Sheng , H Chengnan , L Jong Kalg, *J. Biomed Sci* , **2004** ,11,571 - 578.
- [60] H. Abul , TC Mathew , HM Dashti , A Al-Bader ,*Anat. Histol. Embryol.*, **2002**; 31: 66 - 71.
- [61] A Akbay , K Cinar , O Uzunalmoglo , M Bozkaya , *Human Exp. Tox.* **1999** , 18, 669 - 676.
- [62] H Ammon , A Grimm , S Lutz , *Diabetes.* **1980** ,29, 830 - 834.
- [63] W Frederiks , K D E Bosh , *J. Hist. Cyto.***2003**,51, 105 - 112.
- [64] R M Hartmann , M I Martins , *Effect of Dig Dis Sci.***2012**,57,2038-44.
- [65] SV Sharma , L Thawani, M Hingorani, *Phytomedicine.* **2004**,11,255-260.
- [66] V Afsar , M Reddy, K V Saritha, *Int. J. Life Sci. Biotechnol. Pharm. Res.* **2012**, 1,15-23.
- [67] MC Myhrstad, H Carlsen ,O Nordstrom, *Free Radic Biol Med* .**2002**,32,386 –93.
- [68] G Latella, R Sferra, A Vetusch, E Gaudio, *Eur J Clin Invest.***2008**,38,410-420.
- [69] Sheppard D, *Proc Am Thorac Soc.***2006**,3413-417.
- [70] K Arsalane, C M Dubois, T Muanza , *Am J Respir Cell Mol Bio.***1997**, 17,599-607
- [71] VM Factor , A Kiss, J T Woitach, *J Biol Chem.* **1998**, 273,15846-15853.
- [72] A Marucco, I Fenoglio, F Turci , B Fubini , *Journal of Physics: Conference Series*, **2013**,429 ,1-11
- [73] Y Chang , J Liu , P Lin, L Sun , *Life Sciences.* **2009**, 85,517-525.
- [74] R H Aster, *J Clin Invest.* **1966**, 45,645.
- [75] A Mallik, D Goupale , H Dhongade , S Nayak, *Pharm. Lett.* **2010**, 2,457-463.
- [76] K C Srivastava, *Prost Leuks Med.* **1986**,25,187-98.
- [77] K C Srivastava, A Bordia, S K Verma, *Prost Leuks Essent Fatty Acids* .**1995**,52,223-27.
- [78] L Trusolino, P M Comoglio, *Nat. Rev. Cancer.***2002**, 2, 289–300.
- [79] K Matsumoto, T Nal amura, *Crit Rev Oncogenesis.***1992**, 3,27-54.
- [80] L Naldini , E Vigna, RP Narsimhan, *Oncogene.***1991**,6,501-4.
- [81] H L Huang , Y J Wang, Q Y Zhang, *World J Gastroenterol.* **2012**, 18 6605–6613.
- [82] JN Ade , F Leon, M Pallardy, *Toxicol Sci.* **2009**,107, 451-460.
- [83] U Demirel, M Yalniz, C Aygün , *Inflammation.***2012**,35,1549-57.
- [84] Y Tsujimoto, L R Finger, J Yunis, *Scienc.***1984** 226 , 1097–99.
- [85] M H Kang, C P Reynolds , *Clinical Cancer Research.***2009** ,15, 1126-1132.
- [86] M Emi , R Kim , K Tanabe, *Breast Cancer Research.***2005**, 7,R940-R952.
- [87] LH Chen , CY Hsu , C F Weng ,*World Journal of Gastroenterology* **2006**, 12, 5175-5181.
- [88] S J Lin , S K Shyue , M C Shih , *Atherosclerosis.* **2007**,190,124–34.
- [89] S Y Choi, S H Jung, H S Lee, *Phytother Res.***2008**,22,323-9.
- [90] HI Goldberg, AA Moss, DD Stark, *Radiology.* **1984** , 153,737-9.
- [91] G Zsigmond, A Bodnár , Z Schaff , S Karácsonyi, *Eur Surg Res.***1982**,14,344-57.