



Scholars Research Library
Central European Journal of Experimental
Biology, 2012, 1 (3):77-93
(<http://scholarsresearchlibrary.com/archive.html>)



Evaluating the reversal potentials of hydroalcoholic extracts of *Eclipta alba* in Boric Acid induced male reproductive toxicity

Pooja Nair, Nidhi Vora, Kaveri Purandhar, Vishal Kamle and Sriram Seshadri*

Department of Biochemistry, Institute of Science, Nirma University, Ahmedabad, Gujarat, India

ABSTRACT

Boric acid administration has detrimental effect on different reproductive organs, liver and kidney in rats. In the present study, male Wistar rats were orally fed with boric acid at a dose regimen of 350 mg/kg bodyweight for a period of 30 days, followed by oral administration of hydroalcoholic extract of *Eclipta alba* at a dose regimen of 500 mg/kg body weight orally for 60 days. Boric acid treated group showed signs of toxicity as early as 15 days such as liver damage, nephropathy and complete damage to the testis, which aggravated on 30 days of the boric acid study period. Oxidative stress in all the vital organs showed significant increase. Following the plant extract treatment, complete reversal in reproductive toxicity was observed. The hormonal levels viz., testosterone, estrogen and FSH returned to normal range on the 60 days of plant extract treatment. Significant reversal comparable to the control groups was observed in oxidative stress in the vital tissues. The fertility of the rats was found to be restored. The altered tissue morphology showed significant signs of recovery as observed under light and electron microscopic examination. Thus treatment with the plant extract, the overall recovery in the boric acid treated rats was observed. It can be concluded that Boric acid is definitely having detrimental effects on male reproductive system and the plant extract showed promising results. However, the mode of action and the active components for the same needs to be further investigated.

Key words: Boric Acid, Reproductive Toxicity, *Eclipta alba*, Testis, testosterone, Semen parameters

INTRODUCTION

Reproductive toxicity includes adverse effects on sexual function and fertility in adult males and females, as well as developmental toxicity in the offspring. The major manifestation of developmental toxicity includes death of the developing organism, structural abnormality, altered growth, and functional deficiency.

Boric acid generally is of moderate acute toxicity, and has been placed in Toxicity Category III for most acute effects including oral and dermal toxicity, and eye and skin irritation. Most poisonings by boric acid have occurred in connection with its former use as a local antiseptic applied to irritated skin, burns, or wounds [1]. Within commercial products and the most important minerals that contain boron are the borax pentahydrate, sodium perborate, boric acid, colemanite and ulexite. Different applications for these compounds exist, between which can be mentioned: fiber glass, enamels, fire delays, fertilizers and agricultural herbicides [2].

The target cell for boric acid is elongated spermatid which leads to retention and phagocytosis of step 19 spermatid and abnormalities in released sperm. Failure of spermiation, where the mature testicular sperm fails to be released into the lumen and is instead phagocytized by the Sertoli cell is frequently seen upon administration of boric acid. This reflects a disturbance in the function of the Sertoli cell [3]. Inhibition of spermiation is due to functional changes in the physiology of Sertoli cells. Sertoli cell is thought to be the target for boric acid toxicity [4].

High-dose boric acid (BA) exposure produces testicular lesions in adult rats characterized by inhibited spermiation (IS) that may progress to atrophy. Significant decreases in serum inorganic phosphorus and creatinine were observed that worsened with dose and time of boric acid exposure. Boric acid affect the DNA synthetic activity of mitotic and meiotic germ cells by interfering with the production and/or maturation of early germ cells, thus promoting the testicular atrophy seen in boric acid-exposed rats [5]. The mechanism for the apparent selective testicular toxicity of boric acid remains obscure, and has not been thoroughly studied. One mechanism could be decreased testosterone.

Although research has been carried out with different synthetic compounds for cancer treatment but a limited success has been achieved. The conventional medicinal system provides a valuable tool for therapeutic research. Ayurvedic plants and their components mediate their effects by modulating several of recently identified therapeutic targets. Environmental compounds are known to be involved in both the generation and reversal of toxicity. It is important to discover naturally occurring compounds which can block the toxicity or reverse it.

Extracts of *Hibiscus sabdariffa* (roselle) and *Zingiber officinale* (ginger) reduced the extent of cisplatin-induced sperm abnormality and enhanced sperm motility. Both extracts restored the control level of malondialdehyde (MDA) (lipid peroxidation marker) in the cisplatin-treated testis. The cisplatin injection induced decline in the levels of superoxide dismutase (SOD), reduced glutathione (GSH) and catalase (CAT) were significantly reversed to control levels in groups where cisplatin was preceded by the administration of either *H. sabdariffa* or *Z. officinale*. Thus, both *H. sabdariffa* and *Z. officinale* treatment increased the activities of testicular antioxidant enzymes and restored sperm motility of cisplatin-treated rats [6].

In the present investigation, the hydroalcoholic extract of the leaves of *Eclipta alba* was used to determine its reproductive toxicity reversal potential. *E. alba* has been reported to possess a diverse therapeutic usage such as hepatoprotective activity [7], antinociceptive activity, anti-inflammatory and bronchodilator activity; analgesic activity; immunomodulatory activity, antiviral activity, antioxidant activity and anti hyperglycemic activity, wound healing activity and antifungal activity [8].

MATERIALS AND METHODS

Experimental animals

33 Healthy adult male Wistar rats, weighing 150-250g were procured from Zydus Research Centre, Ahmedabad, compelling to CPSCEA guidelines. The protocol for the present investigation (project no. IS/BIOCHEM//MSC11-12/1016) was approved by Institutional Animal Ethical Committee (IAEC). The Guidance for Care and Use of Animals for Scientific Research (Indian National Science Academy, 2000) was strictly followed. The animals were acclimatized for two months, under controlled condition of temperature ($22 \pm 1^\circ\text{C}$), humidity ($60 \pm 5\%$) and light (12 h light: 12 h dark cycle), prior to the experiments. The animals were monitored every day for their body weight, food and water intake and any visible symptoms, during the whole experiment.

Plant Extract

Dry powder of *Eclipta alba* leaves were obtained from LVG (Ayurvedic product supplier), Ahmedabad and was authenticated by Dr. Vasant A. Patel, Department of Botany, Smt. S.M.P. Science College, Hemachandracharya North Gujarat University, Gujarat, India. Specimen sample of *E. alba* has been submitted at the Institute of Science, Nirma University, Ahmedabad, Gujarat, India with the voucher no. ISNU/EA/CN-120422/01.

Eclipta alba extract (EAE) was prepared by suspending dry leaf powder in 50% ethanol in ratio 1:3 and stirring it overnight at 50°C , followed by filtration under sterile conditions. The filtrate was vacuum dried at 50°C to remove the solvent completely, weighed and reconstituted in water to make 50 mg/ml extract [7].

Chemicals

Boric acid was procured from MERCK, Ahmedabad. All other chemicals were of analytical grade.

Dosage

Boric acid (350mg/kg bodyweight) was dissolved in distilled water and administered orally on a daily basis for 30 days. EAE was administered orally on a daily basis for 60 days at a dose regimen of 500 mg/kg body weight, as determined as the effective dose in other studies carried out in our laboratory [7].

Treatment Schedule

The animals were divided into three groups comprising of 24 animals each in control, Boric acid treated and reversal group (Table 1).

Parameters

The diet and water intake were monitored on daily basis throughout the study duration. Changes in external morphology and hair loss were also observed and monitored. The body weight of all the animals was recorded on a daily basis. The tissue weights of testis, liver and kidney were recorded at the time of autopsy.

Autopsy Schedule

Three animals of each group were sacrificed to study the reproductive physiology by doing autopsy. Three animals from each group were sacrificed at regular interval of 15 days using high concentration of anesthesia. Dissected reproductive organs will be used for histological evaluation and tissue biochemistry. Semen was collected from epididymis for basic semen analysis [9] and the collected blood was preceded for blood profiling and serum biochemical analysis.

Tissue Processing***Histological Studies***

For histological studies, the testis, liver and kidneys were removed at the time of autopsy, cleared of all the fat tissues and was fixed in Bouin's fluid, dehydrated and embedded in paraffin for sectioning at 5µm. These sections were stained with Harris hematoxylin and eosin.

Tissue Biochemistry

Testis, Liver and Kidney were homogenized and frozen at -20⁰c for tissue biochemical assays. At the time of use, the homogenates were thawed and used for the analysis of cholesterol [10, 11] and Protein [12].

Antioxidant Assays

To determine the oxidative stress in the present investigation, Malondialdehyde (MDA) [13] and Reduced Glutathione (GSH) [14] activities were analyzed for all the study group.

Semen Sample Collection

Following autopsy, Sperm were isolated separately from each of the epididymis by gently shearing the tissues and rupturing the tubules, allowing sperm to float into the medium (0.9% N-Saline) [15]. The seminal fluid with the sperm suspended in N. saline for semenological and semen biochemical assessment.

Preparation of Semen Sample

Sperm were separated from seminal plasma by centrifugation and was subjected for various tissue biochemical assays. If tests of sperm function are to be performed, it is critical that the spermatozoa are separated from seminal plasma within 1 hr of collection, to limit any damage from products of non-sperm cells.

Semenology

During semen evaluation, the following parameters were considered. The semen sample was analyzed for its count, motility, viability and morphology. Semenology was performed as per guidelines of WHO manual, [9].

Sperm Functional Tests***Hypo-osmotic swelling***

As an alternative to dye exclusion, the hypo-osmotic swelling (HOS) test may be used to assess vitality [16]. The number of unswollen (dead) and swollen (vital) cells were determined with the aid of a laboratory counter.

Semen Biochemistry

Secretions from the accessory glands were measured to assess gland function. The following organelle marker were assayed, LDH (www.workington-biochem.com/LDH/default.html) and testosterone for testicular function by ELISA, α -glucosidase for Seminal Vesicle functioning, L-Carnitine and glycerophosphocholine (GPC) as epididymal markers and citric acid and acid phosphatase [17] to ascertain the prostate functioning.

Blood Collection

Blood was collected through heart puncture at the time of autopsy in EDTA coated tube. The blood samples were collected in two different tubes. One tube had anticoagulant for the blood count while the second tube was without any anticoagulant for serum analysis and haematocrit parameters respectively. The tube without the anticoagulant was kept in ice box and the supernatant was subjected to centrifugation for serum separation.

Blood Profiling

Hematology of the blood samples was carried out in order to detect the variation in the RBC and the WBC counts. Total white blood corpuscles (WBC), total red blood corpuscles (RBC) and platelet counts were made by using an improved Neubauer's haemocytometer [18]. The haematocrit values Haemoglobin, Packed Cell Volumes (PCV), Mean Corpuscular volume MCV), Mean Corpuscular Hemoglobin (MCH) and Mean Corpuscular Hemoglobin Concentration (MCHC) were recorded according to Natelson, [19] and Lynch et al., [18].

Serum Biochemistry

The serum separated following the blood collection was used for serum biochemical assays. The following parameters were performed i.e., total protein, glucose, cholesterol, creatinine, serum glutamate pyruvate transaminase (SGPT), bilirubin, urea, serum glutamate oxalate transaminase (SGOT), creatinine kinase (CK), triglycerides (TGL) and high density lipoproteins-cholesterol (HDL) were estimated using reagent kits.

Hormone Analysis

The serum samples were also used for the hormonal analysis of testosterone, estrogen and FSH levels using ELISA based kits.

Statistical Analysis

Results are presented as mean \pm SD for 3 animals. A statistical difference between the means of the various groups was analyzed using one way analysis of variance (ANOVA). The statistical significance was evaluated by T-test. The boric acid treated group was compared with the control while the plant extract treated group was compared with the boric acid treated group.

RESULTS

There was no significant trend observed with respect to the daily food and water intake, but there was an increased intake of food as well as water in boric acid treated animals, as compared to the control and plant extract treated group.

The general observation in boric acid treated group was, these animals showed hair loss and drop in their body weight which was not observed in other groups (Data not shown).

Histological Studies**Testis**

The micrograph of testis in vehicle treated control animals reveals normal arrangement of the internal structure of the seminiferous tubules (indicated by thick arrow). The tubules were observed to be connected through interstitial space containing endocrine cells, Leydig cells (indicated by thin arrow). Sperm accumulation was observed in the seminiferous tubules (Figure 1a).

Following 15 day of boric acid treatment, the histological studies revealed gradual degradation of the seminiferous tubules and complete degeneration of the interstitial space was observed i.e., leydig cell were almost absent

following 30 days of boric acid treatment. The internal arrangement of the seminiferous tubules was also observed to be completely distorted. The lumen of seminiferous tubule was completely devoid of any sperm accumulation (Figure 1b-c).

Re-appearance of the connecting tissue was observed in testis after completion of 30 days of plant extract treatment indicating restoration of the Leydig cells (LC). The internal arrangement of the seminiferous tubules (ST) was also observed comparable to that of control. A gradual restoration of the testis function was observed in animals following 60 days of plant extract treatment. The interstitial space was observed to redevelop at a steady rate. Sperm accumulation was observed to initiate after 60 days of PE treatment indicating a speedy recovery (Figure 1d-e).

Liver

The micrograph of liver of vehicle treated control animals revealed that the liver lobule contains a number of hepatic acini and each centred on a portal tract. The tissue also contains sparse collagenous tissue acting as cushion for development and functioning of the acini. The hepatic venules were also observed on the terminal of the hepatocytes. The spacing between the hepatic cells was observed to be regular (Figure 2a).

The arrangement of the hepatocytes in 15 and 30 days boric acid treated animals was found to increase compared to that of the vehicle treated control animals. The collagenous tissue was completely absent in the tissue. The hepatic venule was observed to be enlarged while the portal tract was also observed to be damaged (Figure 2b-c). The damage to the liver was also associated with the infiltration of blood cells indicative of inflammatory activity which was noted throughout the section (Indicated by arrow).

After 30 days of plant extract treatment, the collagenous tissue was observed to reappear. Healing in the portal tract was also observed. The spacing between hepatic cells was observed to reduce compared to that of the boric acid treated group, but the arrangement was still irregular (Figure 2d).

A gradual re-development of the hepatic tissue was observed following the 60 days of PE extract treatment. The spacing between the hepatocytes was observed to condense compared to that of the boric acid treated groups animals, almost comparable to that of the control. The collagenous tissue was observed to re-appear in the tissue in a stepwise manner. The hepatic venules were also observed that were comparable to that of the vehicle treated control animals.

Although, the histoarchitecture of the liver recovered back to normalcy, there were still occurrence of blood cell accumulation but these accumulation were significantly reduced compared to boric acid treated group, indicating that the extract also possess anti-inflammatory potentials which need to be ascertained in future (Figure 2e-f).

Kidney

The micrograph of kidney of vehicle treated control animals illustrates renal corpuscles appeared as dense and glomeruli surrounded by a narrow Bowman's space. The cortical tubules were observed which mainly consist of proximal convolute tubules and with a smaller number of cortical tubules and collecting ducts. The average diameter of the renal corpuscles was found to be 0.3μ in all the treatment groups (Figure 3a).

A partial de-arrangement of the cortical tubule was observed in 15 day boric acid treated animals. The Bowman's space was also found to increase around the glomeruli compared to that of the vehicle treated control animals. The proximal convolute tubules and cortical tubules were also observed to be damaged. Following 30 days of boric acid treatment, complete de-arrangement of the cortical tubule was observed. The Bowman's space was significantly increasing, indicating damage to kidney (Figure 3b-c).

Completion of 30 days of plant extract treatment period, a gradual recovery was observed in kidney. Bowman's space was observed to reduce compared to that of the boric acid treated group, while in proximal convolute tubules and cortical tubules rearrangement was observed. A speedy recovery was observed in kidney following 60 days of the PE treatment. The Bowman's space was reduced compared to that of the boric acid treated groups. The corpuscles re-arrangement was also observed to recover at a faster pace. The proximal tubules were also observed to be normal, almost comparable to that of the control (Figure 3d-f).

Tissue Biochemistry

Significant elevation in the cholesterol content was observed in 15 and 30 day boric acid treated, following the plant extract treatment, the levels were restored to the normal range comparable to that of the control group. There was a sudden decline in the protein content when treated with boric acid. Following the plant extract treatment the protein content was restored comparable to that of the control group (Table 2).

Antioxidant Assays

Malondialdehyde (MDA) and Reduced Glutathione (GSH) were estimated in tissue extract of testis to ascertain the oxidative stress at the testicular level. There is a sudden decline in the MDA level in the boric acid treated animals but after the plant extract treatment the level was restored to normal range comparable to that of the control group. The GSH level showed significant increase in boric acid treated animals but there was a sudden decline after the plant extract treatment (Graph 1).

Semenology

The sperm count in the boric acid treated animals was found to decline, which recovered to the normal range following the plant extract treatment. The sperms were completely non-motile in boric acid treated, which recovered to the fertile range in the plant extract treated animals. The sperm obtained in the boric acid treated group were all dead, rendering the sperm completely infertile. The viable count increased following 30 days of extract administration and which further improved at 60 days study period. The percentage of abnormal morphology had increased after 15 days of boric acid treatment while following the plant extract treatment, the abnormality was slightly reduced (Table 3).

Sperm Functional Test

Hypo-osmotic swelling

HOS had shown significant reduction from 67% in control group to 35% in 15 days boric acid treated group i.e., the sub-fertile range. This further dropped to 2% in the 30 day boric acid treated group. However, following plant extract treatment, in 30 days PE administered group the levels were found to be in the fertile range i.e., 45%, which gradually improved to 62% at the end of 60 days of PE study period (Data not shown).

Semen Biochemistry

Following treating rats with boric acid, there was a significant increase in the LDH levels, indicating the extent of damage at the testicular level. A gradual decrease in LDH levels was observed following treatment of plant extract, values were comparable to that of the control group (Table 4).

α -Glucosidase, seminal vesicle tissue marker decrease in boric acid treated group which recovered following plant extract treatment. Epididymal Markers L-Carnitine and glycerophosphocholine showed different trend. L-carnitine was found to be increasing, while there was a decrement in the GPC level in boric acid treated animals. The L-carnitine levels fluctuated whereas the GPC levels increased following plant extract treatment (Table 4).

A decrease in the activity of prostate specific acid phosphatase and citric acid was found in boric acid treated. The ACP values were found to increase at a steady rate following the plant extract treatment, but the citric acid levels dropped below the normal range. Although, the administration of the plant extract recovered the altered prostatic markers, however, it did not resulted in any changes with respect to the declining citric acid levels, which did not return back to normalcy even after 60 days of plant extract administration (Table 4).

Blood Profiling

Hematology

In vehicle treated control animals, all the hematological parameters were found within the normal range. A significant decrease was observed in haemoglobin, total RBC, platelet count, PCV, MCV and MCH except for MCH and MCHC count, following boric acid treatment. Following 60 days of plant extract treatment, all the altered parameters were restored to normal range comparable to that of the control group. Although WBC count showed a recovery as comparable to the 30 days boric acid toxicity induced group but did not return to normalcy till the study period (Table 5).

Serum Biochemistry

Serum biochemical analysis of the control group for Glucose, Protein, HDL cholesterol, Triglyceride, Creatinine, Urea, Total Bilirubin, Direct Bilirubin, serum glutamate pyruvate transaminase (SGPT), Serum glutamate oxaloacetate transaminase (SGOT) and Creatinine kinase-MB showed these values within the normal physiological range. The values obtained were 103.6 ± 0.17 mg/dl, 8.3 ± 0.26 g/dl, 165.8 ± 7.16 mg%, 61.6 ± 0.73 mg/dl, 2.0 ± 0.70 mg/dl, 5.0 ± 0.30 mg/dl, 4.3 ± 0.27 mg/dl, 1.9 ± 0.21 mg/dl and 4.59 ± 0.22 U/IAST, 4.6 ± 0.20 U/ALT and 18.02 ± 0.09 U/I respectively.

Following 15 days and 30 days boric acid treatment, all the serum enzyme activity i.e., SGOT, SGPT and CK-MB, was found to increase and the non-enzymatic parameters showed significant decrease at the end of 30 days of boric acid treatment. Following administration of the plant extract, all the altered parameters were restored back to normalcy (Table 6).

Hormone Analysis

The serum testosterone estimation was concurrent to the alteration in the serum biochemical parameters, which showed a drop following boric acid treatment and improved significantly following the plant extract treatment. The concentration obtained for vehicle treated control group and boric acid treated group were 1.08 ± 0.05 ng/ml and 0.59 ± 0.04 ng/ml respectively. The value estimated following 30 days and 60 days of plant extract treatment was found to be 0.71 ± 0.05 ng/ml and 1.09 ± 0.02 ng/ml, respectively (Table 7).

The estrogen concentration in vehicle treated animals was 47.485 ± 0.23 pg/ml, while the level was found to be decreasing in 30 day boric acid and plant extract treated animals. The values estimated were 32.0 ± 2.54 pg/ml and 24.84 ± 1.34 pg/ml respectively. After 60 days of plant extract treatment, the value estimated was 38.5 ± 2.22 pg/ml which indicates that there is significant improvement than the boric acid induced group (Table 7).

The FSH concentration in vehicle treated animals and boric acid treated animals were 0.32 ± 0.035 mIU/ml and 0.33 ± 0.030 mIU/ml respectively. A sudden decrease in the level was observed after 30 days of plant extract treatment. The value estimated at the 30th day of plant extract treatment was 0.11 ± 0.04 mIU/ml. After 60 days of plant extract treatment the level was restored to normal range and estimated value was 0.3 ± 0.02 mIU/ml (Table 7).

DISCUSSION

Boric acid falls under suspected reproductive toxicant. Boric acid generally is of moderate acute toxicity, and has been placed in Toxicity Category III for most acute effects including oral and dermal toxicity, and eye and skin irritation. Most poisonings by boric acid have occurred in connection with its former use as a local antiseptic applied to irritated skin, burns, or wounds. The fatal dose is thought to be 2,000 – 3,000 mg for infants, 5,000 – 6,000 mg for children and 15,000 – 20,000 mg for adults. EPA classified boric acid as a “Group E” carcinogen, indicating that it shows “evidence of noncarcinogenicity” for humans [1].

Eclipta alba is a small evergreen tree with wide geographical and ecological distributions and its certain parts are used as medicinal materials. *E. alba* are drought evergreen plants of the family asteraceae. This plant grows as a common weed throughout India. Its phytochemical constituents are: wedelolactone and demethyl-wedelolactone, stigmasterol, -terthienymethanol, desmethyl-wedelolactone-7-glucoside, unnamed alkaloid, apigenin, luteolin and their glucoside, wedelic acid, 25- -hydroxyverazine, ecliptine and nicotine [20]. Roots of *E. alba* have been reported with thiophene acetylenes such as 5I-senecioid oxymethylene-2- (4-isovaleryloxybut- 3-ynyl)- dithiophene, 5I-tigloyloxymethylene- (isovaleryloxybut- 3-ynyl) dithiophen and 2-(3-acetoxy-4-chloro-but-1-ynyl)-5-(pent-1,3-diynyl) thiophene, hentriacontanol, stigmasterol, ecliptal, 14-heptacosanol. Stems contain wedelolactone, wedelic acid, L-terthienyl methanol, apigenin, luteolin. Seeds of *E. alba* contain sterols [21, 22].

E. alba extract has been used for ascertaining various biological activities such as anti-bacterial effect [23, 24], Anti-hepatitis activity [25], anti-hyperglycemic effect [8] and hepatoprotective activity [7, 8].

With the literature available so far, numerous properties of *E. alba* is known. But there are no reports available with respect to the efficacy of *E. alba* extract on male reproductive system. Therefore, to determine its potential effects in reversal of reproductive toxicity the study was designed and carried out.

Although, the food and water intake had increased there was a notable drop in the body weight of boric acid induced animals. The justification for it is not known. According to the reports of Aysan et al., [26], low-dose (0.2mg/kg) oral boric acid intake cause seriously body weight reducing in five days. A toxicology study done by the US Department of Health and Human Services demonstrated that 275 and 550 mg of boric acid per kg of body weight per day intake mice reduced body weights 10-17% after 32 weeks.

After the treatment with the boric acid, profound testicular changes were observed. The internal arrangement of the seminiferous tubules was completely damaged. This indicates that the Sertoli cells located in tubules are damaged, as consequences of which sperm generation and maturation is also disturbed, which was observed by studying semenology. No sperm accumulation was observed indicating dysfunction of the Sertoli cells. The interstitial space was observed to be damaged. Hence Leydig cells located in the interstitial space were also degenerated. Result obtained in this study was found to be similar also reported by Traina et al., [27]; Ronco et al., [28] and Suwalsky et al., [29], reported an increase in the size of Leydig cells following the lindane treatment, on the contradictory, our studies revealed the degeneration of the leydig cells, which was similar to the finding reported by Ananya et al. [30].

A gradual and slow re-development of testis was observed following the plant extract treatment. On completion of the treatment the arrangement of the Sertoli cells in the seminiferous tubules was almost comparable to that of the vehicle treated control animals. The sperm accumulation was also observed and semenology study reveals that sperm generated were properly matured indicating the proper functioning of the Sertoli cells, which were degenerated following the boric acid treatment. The interstitial space was also observed to re-develop following the plant extract treatment. This indicates that Leydig cells were re-generated following the plant extract treatment.

Fail et al. [31] emphasize that few studies exist on the chronic effects of boron in humans and a similar number in experimental animals, most of which are focused on its reproductive and developmental effects. The most documented reproductive damage corresponds to alterations of the spermatogenesis and degeneration of the seminiferous epithelium, indicating the necessity to extend the study of the toxicity of boron to other tissues.

The toxic effect of boron occurs beyond the function of the hepatocytes, altering the production of collagen on the part of the cells of Ito, the fibroblasts and endothelial cells [32].

Profound histological changes were observed in 30 days boric acid treated animals. The inter hepatocyte spacing was noted to increase following the boric acid treatment. This may due to disturbance in the cell to cell interaction by inhibition of the gap junction. The blood supply to the cell was also disturbed and the cellular clumps were visible. The cushion protective collagenous tissue was also not observed in liver.

A proper re-arrangement of the tissue was observed following the plant extract treatment. The gradual re-development of the blood supply was observed in the cell. The portal tract was observed to be normal indicating the blood supply is almost comparable to that of vehicle treated control animals. The clumps were not observed after 60 days of plant extract treatment. The cellular arrangement was observed to be regular, indicating restoration of the gap junction and cellular interaction. Thus plant extract treatment reveals the hepatoprotective properties of the plant extract.

The basic unit of the kidney is nephron, consisting of renal corpuscles (initial filtering component). Boric acid treatment has increased the Bowman's space in renal corpuscles and also disturbed the PCT and DCT. The concentration of the urea was also observed to be altered indicating renal failure.

During the course of the plant extract treatment a gradual recovery was observed in kidney. At the end of the treatment, Bowman's space was almost comparable to that of the vehicle treated control animals. Proper arrangement of the PCT and DCT was also observed, indicating the proper functioning of the nephron. Thus, after plant extract treatment, the nephropathy had been observed to be reversed and proper functioning of nephron was reestablished.

Significant elevation in the tissue cholesterol content was observed following 30 days of boric acid treatment. The concentrations of cholesterol, an essential structural component of membranes and the precursor of all steroid hormones, may increase due to liver and kidney failure causing the release of cholesterol into the blood. The result

found in the present study is concurrent to the results observed by Furat et al., [33], which reports that the total cholesterol content increases in *Oreochromis niloticus*, a fish, when exposed to a pesticide, cypermethrin and two metals (copper and lead). After 60 days of plant extract treatment, the cholesterol content was retained to normal range compared to that of the vehicle treated control animals.

The histological observations were confirmed by the tissue biochemical parameters. Following boric acid treatment, a significant decline in the protein content of the tissue was noted. This might be due to inhibition of protein synthesis.

Tissue biochemistry in all treatment groups was performed to determine the oxidative stress prevailing in the tissue. ROS (reactive oxygen species) are an important part of the defense mechanism against infection, but excessive generation of free oxygen radicals may damage tissues. ROS are formed in both physiological and pathological conditions in mammalian tissues. ROS includes superoxide anion, hydroxyl radical, hydrogen peroxide and oxygen ion, all of which are unstable and fully reactive to attack molecules in the body resulting in ROS conversion to stable atoms and molecules [34]. When the balance between ROS and antioxidant system is lost 'oxidative stress' results [35]. Oxidative stress is one of the major factors for induction of cancer [36].

The MDA levels are determined as an index of Lipid peroxidation and it is one of the main manifestations of the toxicity and carcinogenesis of many carcinogens [37, 38]. The marked increase in MDA content after aflatoxin B1 (AFB₁) exposure could contribute to the effect on antioxidant defense system [39]. On the contradictory in our studies, there is a decrement in the MDA level in testis and prostate following 30 days of boric acid treatment.

After the boric acid treatment, the GSH concentration was found to decline in epididymis and prostate, whereas in testis there was a significant elevation. The variation observed in GSH, indirectly indicated high generation of free radicals in the tissue, which was also observed by Turkez et al., [39]. This may cause decreased degradation of lipid peroxides leading to their accumulation thus amplifying the toxicity.

Following the treatment with plant extract, the concentration of GSH and MDA was observed to restore to normalcy. This indicates there is a decline in the free radical generation. Thus the plant extract exhibits free radical scavenging property, and helps in maintaining the relationship between exogenous and endogenous ROS, reducing the oxidative stress on the tissue. A similar result was reported by Ahmed et al., [40] using extract of *Zingiber officinales*, in liver antioxidant study.

A decrease in the epididymal sperm count was observed following the boric acid treatment which was also observed by Prasad et al., [41]. Sperm viability was also observed to reduce along with the sperm functional test. This indicates the induction of infertility in male rats in boric acid treated groups. A similar result was observed by Fausto et al., [42] in male rabbits. The decrease in the epididymal sperm count can also be confirmed with the histopathological studies of testis.

A complete reversal or restoration of the activity of sperm and sperm function was observed comparable to that of the vehicle treated control animals following the plant extract treatment. The viability was observed to be restored to almost comparable to that of the vehicle treated control. The sperm count was observed to be normal following plant extract treatment. A regeneration of the proper arrangement of the testis was also observed. The sperm functional analysis was also noted to be almost comparable to vehicle treated control animals.

LDH-C4 is an isoenzyme associated with testis, normally used as marker for determining proper functioning of the reproductive organs [43]. An increase in the LDH-C4 value indicates that the sperm mitochondrial activity has declined; indicating improper functioning of the sperm and its maturation. Analysis of semen biochemistry showed an increased value of LDH-C4 in boric acid treated animals group. The increase in the activity of LDH-C4 indicates function of the mitochondria had been hampered. Moreover LDH plays a major role in metabolic activity (glycolysis). Rupturing of the spermatids, results in release of contents from sperm head, neck and midpiece. Thus, leading to increase in the LDH activity.

The estimation of α -glucosidase activity in semen is widely used as a marker of epididymal function [44]. Epididymal α -glucosidase does not play a crucial role in the development of sperm fertilizing capacity, but may be involved in the preparation of spermatozoa for storage [45]. The decrease in the enzyme activity has been in

observed non-azoospermic men [46]. A decrease in the activity was observed in the boric acid treated animals, indicating conditions of infertility in animals.

The epididymal marker, L-carnitine was found to be increasing in boric acid treated animals. This is because L-carnitine has antioxidant potentials thereby protecting against oxidative stress [47]. The increase in L-carnitine levels are also confirmed by increase in antioxidant levels and damage caused in the epididymis.

The other epididymal marker, GPC was found to be decreasing following the boric acid treatment. GPC has a role in motility of the sperm [48]. A decrease in GPC levels results in reduction of motility which is concurrent to the results obtained in the present study.

A decrease in the activity of prostate specific, acid phosphatase and citric acid was found in boric acid treated animals. Acid phosphatase is associated with sperm motility [49]. This indicates a decline in the sperm motility due to decrease in ACP activity. Hypo-osmotic swelling test is also used to determine the sperm motility [16]. A reduction in the coiling was observed in the boric acid treated animals, justifying the reduction in ACP activity.

A significant decrease was observed in haemoglobin, total RBC, platelet count, PCV, MCV and MCH except for MCH and MCHC count, following boric acid treatment. Decrease in hemoglobin in experimental animals might be due to destruction of erythrocytes and inhibition of erythropoiesis, which is confirmed by decreased MCHC Values. Similarly, significant decrease in the haematological parameters was observed in fish when exposed to Sevin, a pesticide [50].

After 60 days of plant extract treatment, all the altered parameters were restored to normal range comparable to that of the control group.

Boric acid had been observed to have damaged the function of the tissue namely liver, kidney and testis. Hence, there has been a drastic change in the serum profile of the animals. The serum enzyme, namely alkaline CK-MB, SGOT and SGPT were observed to increase drastically after the boric acid treatment. The increase in the enzymes indicates the functioning of the hepatocytes has been disturbed, releasing the enzymes in circulatory system.

The non-enzymatic parameters showed significant decrease at the end of 30 days of boric acid treatment. The concentration of glucose was observed to decrease. Thus treatment with boric acid, hypoglycemic condition aroused, indicating that the glycogen metabolism and gluconeogenesis has been disturbed. The insecticide, thiamethoxam, has been found to cause a reduction in serum cholesterol that precedes liver histopathological changes similar to those observed in the present study [51]. These authors interpreted the low cholesterol as an early sign of liver dysfunction. Along with glucose, cholesterol and HDL cholesterol was also observed to decrease. The primary purpose of HDL is to act as the acceptor of cholesterol released from tissues outside the liver and transport it back to the liver [52].

In an experiment on male rabbits exposed to lead toxicity, the elevated serum cholesterol level was significantly lower in the treatment group in which lead was given along with garlic, a natural food containing important nutrients and antioxidants [53].

HDL-cholesterol is not recycled for cholesterol uptake from different tissue indicating imbalance in the cholesterol metabolism. The concentration of urea was noted to be decreasing following the boric acid treatment. The decrease in the serum urea level indicates impairment in the kidney/nephron function, which was also observed in the histopathological study of kidney.

The plant *E.alba* has been shown to have hepatoprotective activities [8]. After treatment with the plant extract, the activity of the serum enzymes was observed to restore to normalcy. This indicates the repair of the damaged tissue following the treatment. The concentration of the cholesterol and HDL-cholesterol was also observed to increase after the course of plant extract treatment. Similar results were obtained when *Physalis angulata* was administered to rats [54]. In the present investigation, the concentration of urea was restored to normalcy after 60 days of treatment period, indicating recovered functioning of the nephron.

The serum testosterone estimation was concurrent to the alteration in the serum biochemical parameters, which showed a drop following boric acid treatment and improved significantly following the plant extract treatment.

Testosterone is specifically produced by Leydig cells containing enzyme 11 β -hydroxysteroid dehydrogenase [55]. The concentration of testosterone was observed to decline after the 30 days of boric acid treatment. Histological studies of the testis had revealed the degeneration of Leydig cells during the boric acid treatment, which is confirmed by decline in testosterone level; compared to that of the vehicle treated control animals. Following the plant extract treatment, regeneration of the Leydig cells was observed, which was confirmed by increase in the testosterone level, almost comparable to that of the vehicle treated control animals.

Elevations in serum FSH levels suggested an intact hormonal response to the testicular atrophy [56]. There was slight elevation in FSH levels after 30 days of boric acid treatment. Following 30 days of plant extract treatment, the level declined, which was restored in the normal range after 60 days of plant extract treatment. Serum FSH levels were lower in animals treated with plants extracts of *Cynomorium coccineum* and *Withania somnifera* [57]. Another report by Udoh et al., [58] (2009), states that when alkaloid extract of caricapryl-99 seeds is administered to male albino rats, it caused increase in serum levels of FSH and estrogen.

Table 1: Treatment Groups

Group No.	Treatment Group	Number of Animals
1.	Control Group	9
2 (a)	Boric Acid induced Toxicity group @350mg/kg bodyweight/day/rat for 30 days	24
2 (b)	EAE treated group following Boric acid induced toxicity @ 500 mg/kg body weight/day/rat for 60 days	18

Table 2: Tissue Biochemical Analysis of Control, following Boric Acid toxicity and plant extract treatment groups

GROUPS	CONTROL	15 DAY BA	30 DAY BA	30 DAY PE	60 DAY PE
CHOLESTEROL (mg/g of tissue)					
TESTIS	3.4 \pm 0.04	7.2 \pm 0.33*	8.3 \pm 0.24*	6.9 \pm 0.20***	3.8 \pm 0.020**
LIVER	0.7 \pm 0.03	3.2 \pm 0.63*	4.9 \pm 0.05*	3.2 \pm 0.43**	2.1 \pm 0.034**
KIDNEY	0.9 \pm 0.02	3.7 \pm 0.403*	5.3 \pm 0.27*	4.2 \pm 0.38***	2.0 \pm 0.028**
PROTEIN(mg/g of tissue)					
TESTIS	9.3 \pm 0.28	6.4 \pm 0.56*	5.8 \pm 0.42*	7.0 \pm 0.03***	8.7 \pm 0.05*
LIVER	7.5 \pm 0.27	6.3 \pm 0.25**	4.5 \pm 0.22*	5.6 \pm 0.40***	6.80 \pm 0.63***
KIDNEY	8.5 \pm 0.43	6.2 \pm 0.62**	5.3 \pm 0.33*	6.3 \pm 0.35***	7.38 \pm 0.022**

All values are mean \pm SD for 3 rats. *: $p \leq 0.0001-0.0006$, **: $p \leq 0.0007-0.005$, ***: $p \leq 0.006-0.05$

Table 3: Semen Analysis of Control, following Boric Acid toxicity and plant extract treatment groups

GROUPS	CONTROL	15 DAY BA	30 DAY BA	30 DAY PE	60 DAY PE
Sperm count (10⁶/ml)	7.1 \pm 0.3	3.2 \pm 1.21	1.8 \pm 0.54	8.1 \pm 0.30	8.5 \pm 0.50
Motility (%)	67.00 \pm 6	-	-	57.8 \pm 5.29	61.1 \pm 0.98
Vitality (%)	66.0 \pm 2.51	-	-	2.33 \pm 0.57	1.0 \pm 0.23
Abnormal Morphology (%)	10.6 \pm 1.52	75.0 \pm 2.57	90.8 \pm 12.73	46.6 \pm 2.51	37.0 \pm 2.25

All values are mean \pm SD for 3 rats.

Table 4: Seminal plasma biochemical assessment of Control, following Boric Acid toxicity and plant extract treatment groups

PARAMETERS		GROUPS				
		CONTROL	15 DAY BA	30 DAY BA	30 DAY PE	60 DAY PE
	LDH (unit/ml)	53.2 \pm 0.305	60.1 \pm 8.21*	70.0 \pm 3.40*	65.6 \pm 0.50	58.7 \pm 7.84*
	α-glucosidase (μmol/l)	3.1 \pm 0.09	1.9 \pm 0.87***	1.3 \pm 0.11*	1.8 \pm 0.25***	2.7 \pm 0.78*
	L-Carnitine (g/dl)	0.15 \pm 0.016	0.23 \pm 0.04***	0.26 \pm 0.02***	0.35 \pm 0.05***	0.17 \pm 0.02***
	GPC (mmol/L)	0.31 \pm 0.018	0.18 \pm 0.05*	0.09 \pm 0.008**	0.19 \pm 0.36***	0.25 \pm 0.06***
	ACP (U/ml)	20.49 \pm 0.462	17.6 \pm 1.15***	12.7 \pm 0.14*	18.5 \pm 0.22*	21.9 \pm 1.57*
	Citric Acid (mg/dl)	6.59 \pm 0.16	4.2 \pm 0.8*	3.6 \pm 0.91*	3.13 \pm 0.56***	5.4 \pm 1.24***

All values are mean \pm SD for 3 rats. *: $p \leq 0.0001-0.0006$, **: $p \leq 0.0007-0.005$, ***: $p \leq 0.006-0.05$.

Table 5: Hematological and hematocrit values of Control, following Boric Acid toxicity and plant extract treatment groups

PARAMETERS		GROUPS				
		CONTROL	15 DAY BA	30 DAY BA	30 DAY PE	60 DAY PE
	Haemoglobin (gm%)	14.6±0.40	12.1±0.35 *	11.9±0.40 **	11.0±0.05 **	14.0±0.35 **
	Total W.B.C (10 ³ /c.mm)	11.7±0.56	2.5±0.80	1.9±0.02	4.9±0.90 *	6.9±0.40 *
	Total R.B.C (10 ⁶ /C.mm)	7.8±0.07	6.1±0.16 *	5.1±0.08	6.2±0.20 *	7.1±0.20 *
	Platelet Count (10 ⁶ /c.mm)	7.0±0.07	4.3±0.31 *	6.0±0.34 **	7.0±0.81 **	7.9±0.02 **
	P.C.V (%)	46.6±0.66	34.0±5.56 ***	29.6±6.5 **	31.2±0.17	41.5±.31 ***
	M.C.V (fl)	60.0±0.98	55.7±0.50 ***	52.1±0.87 *	50.9±0.16 ***	53.5±0.16 ***
	M.C.H (pg)	18.7±0.40	19.8±0.60 ***	23.0±0.15 **	21.2±0.87 ***	18.3±0.28 *
	M.C.H.C (%)	31.3±0.55	34.6±0.55 *	38.7±0.32 *	31.1±0.08 *	34.6±0.58 **

All values are mean ± SD for 3 rats. *: $p \leq 0.0001-0.0006$, **: $p \leq 0.0007-0.005$, ***: $p \leq 0.006-0.05$.

Table 6: Serum Biochemical Analysis of Control, following Boric Acid toxicity and plant extract treatment groups

PARAMETERS		GROUPS				
		CONTROL	15 DAYS BA	30 DAYS BA	30 DAYS PE	60 DAYS PE
	GLUCOSE (mg/dl)	103.6±0.17	52.1±0.33 *	49.7±0.42 *	92.2±0.02 *	101.3±0.32 *
	Protein (g/dl)	8.3±0.26	5.0±0.33 *	4.7±0.15 *	2.8±0.25 **	6.0±0.32 ***
	HDL-Cholesterol (mg%)	165.8±7.16	77.6.3±2.89 *	60.6±1.55 *	84.8±0.29 **	102.5±0.42 *
	Triglyceride (mg/dl)	61.6±0.73	97.06±9.60 ***	108.1±5.56 *	87.0±0.14 ***	53.0±0.46 *
	Creatinine (mg/dl)	2.0±0.70	0.86±0.04 ***	0.5±.025 **	0.8±0.36 ***	1.1±0.60 ***
	Urea (mg/dl)	5.0±0.30	1.3±0.43 ***	0.8±0.17 ***	1.4±0.20 ***	3.3±0.77 *
	Total Bilirubin (mg/dl)	4.3±0.27	2.6±0.20 *	1.0±0.44 *	2.8±0.05 **	3.9±0.51 *
	Direct Bilirubin (mg/dl)	1.9±0.21	1.1±0.37 *	1.3±0.26 **	0.93±0.26 **	0.96±0.05 ***
	SGPT(U/IAST)	4.5±0.22	2.3±0.20 **	6.6±0.27 *	5.8±0.15 ***	4.3±0.81 *
	SGOT(U/IALT)	4.6±0.20	6.9±0.16 *	9.3±0.10 *	7.8±0.20 ***	5.7±0.84 **
	CK-MB(U/I)	17.9±0.09	16.8±0.22 ***	20.1±0.34 **	19.2±0.56 **	18.7±0.94 **

All values are mean ± SD for 3 rats. *: $p \leq 0.0001-0.0006$, **: $p \leq 0.0007-0.005$, ***: $p \leq 0.006-0.05$.

Table 7: Testosterone, Estrogen and FSH levels of Control, following Boric Acid toxicity and plant extract treatment groups

Treatment Groups	Testosterone (ng/ml)	Estrogen (pg/ml)	FSH (mIU/ml)
Control	1.08±0.05	47.485±0.23	0.32±0.035
Boric Acid 30 days	0.59±0.04*	32.0±2.54*	0.33±0.030 *
Plant Extract 30 days	0.71±0.05 ***	24.84±1.34 **	0.11±0.04**
Plant Extract 60 days	1.09±0.02*	38.5±2.22 ***	0.3±0.02 ***

All values are mean ± SD for 3 rats. *: $p \leq 0.0001-0.0006$, ***: $p \leq 0.006-0.05$.

Figure 1 a-e: Histological section of testis of Control, following Boric Acid toxicity and plant extract treatment groups. Thick arrows indicate seminiferous tubules and thin arrow indicated Leydig cells.

Figure 1a: Control Group

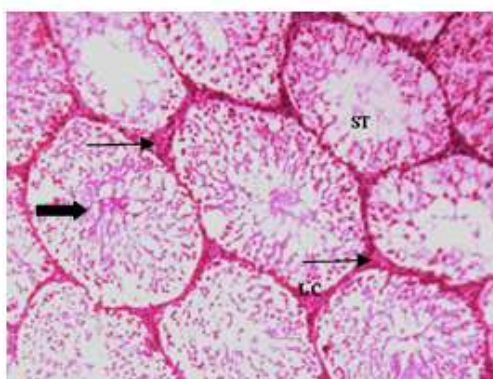


Figure 1b: 15 Days Boric Acid Group

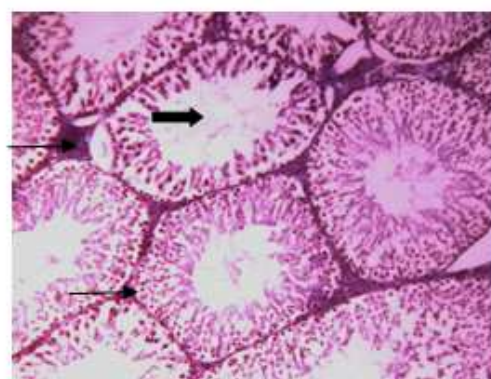


Figure 1c: 30 Days Boric Acid Group

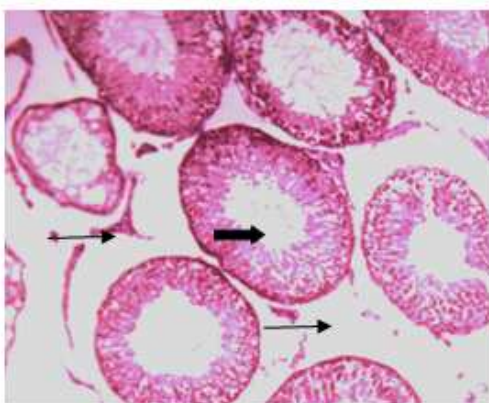


Figure 1d: 30 Days Plant Extract Group

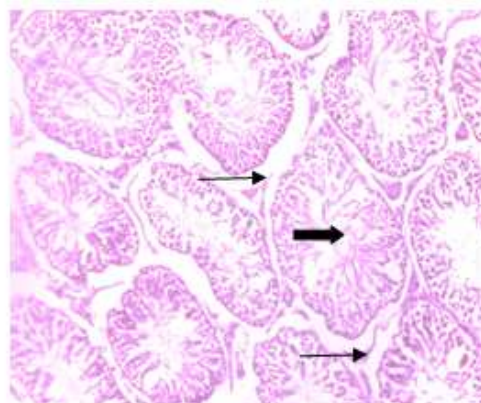


Figure 1e: 60 Days Plant Extract Group

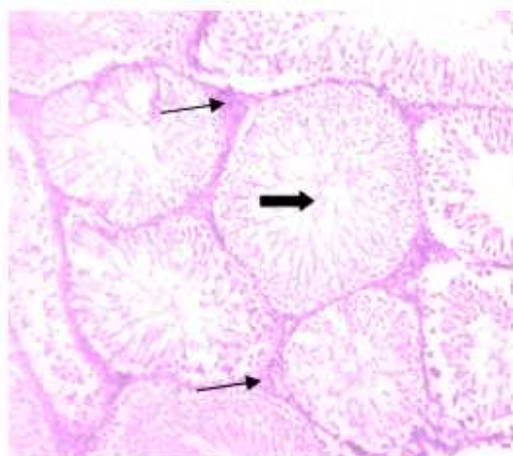


Figure 2a-f: Histological section of Liver of Control, following Boric Acid toxicity and plant extract treatment groups. Thin arrow indicated Sinusoids and accumulation of blood cells.

Figure 2a: Control Group

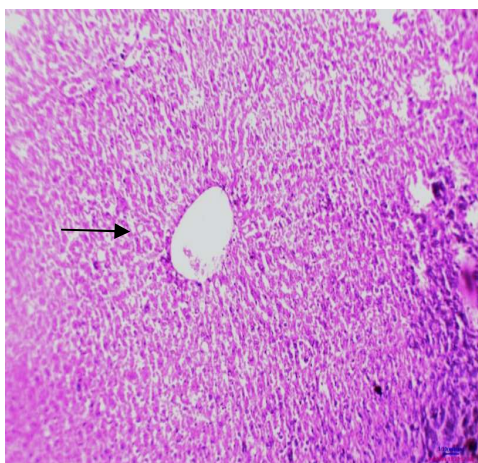


Figure 2b: 15 Days Boric Acid Group

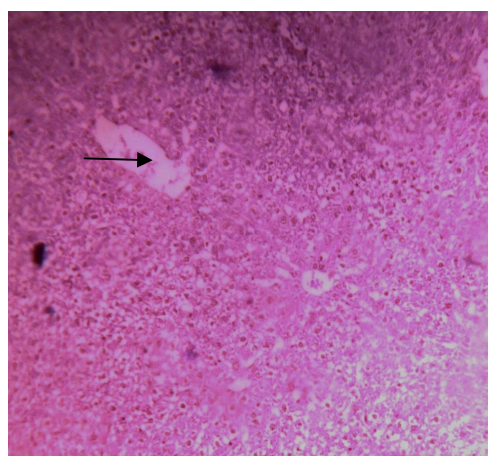


Figure 2c: 30 Days Boric Acid Group

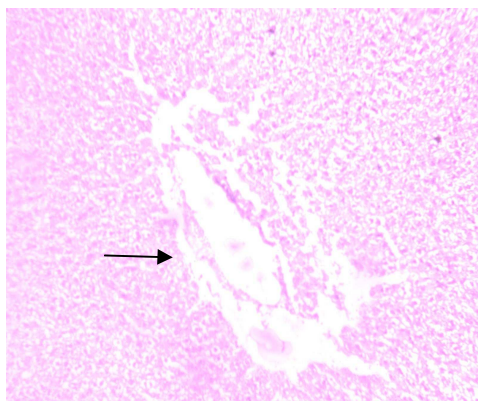


Figure 2d: 30 Days Plant Extract Group

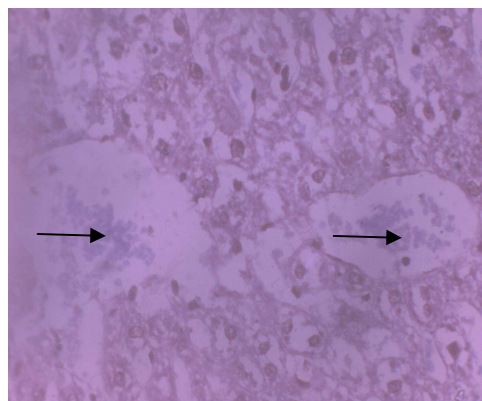


Figure 2e: 60 Days Plant Extract Group

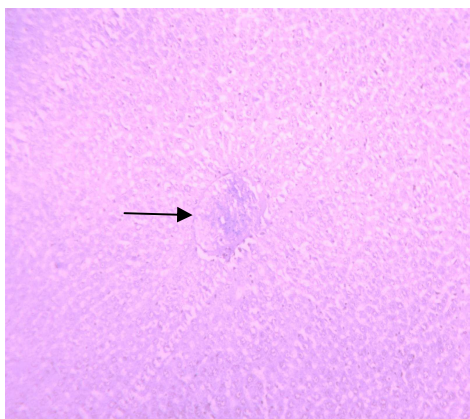


Figure 2f: 60 Days Plant Extract Group

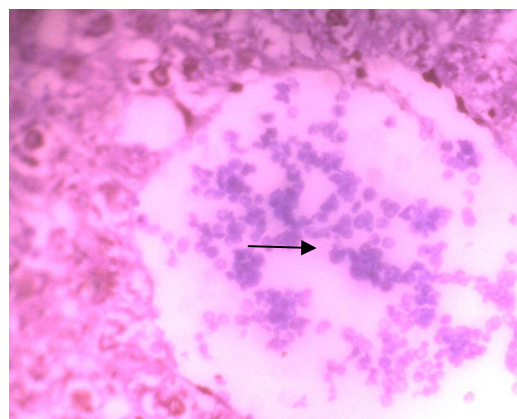


Figure 3a-f: Histological section of Kidney of Control, following Boric Acid toxicity and plant extract treatment groups.

Figure 3a: Control Group

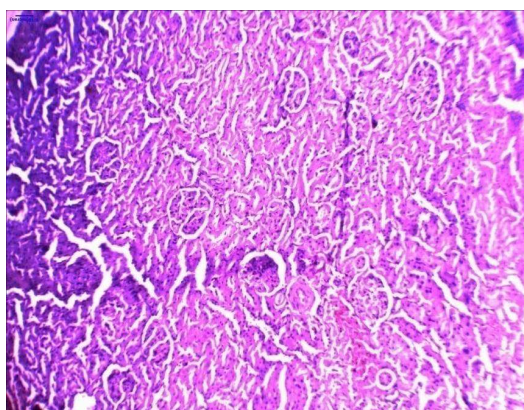


Figure 3b: 15 Days Boric Acid Group

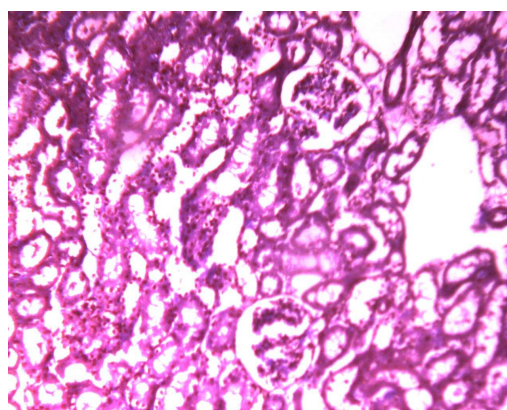


Figure 3c: 30 Days Boric Acid Group

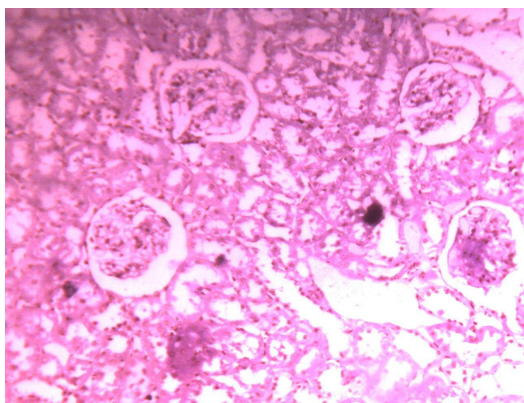


Figure 3d: 30 Days Plant Extract Group

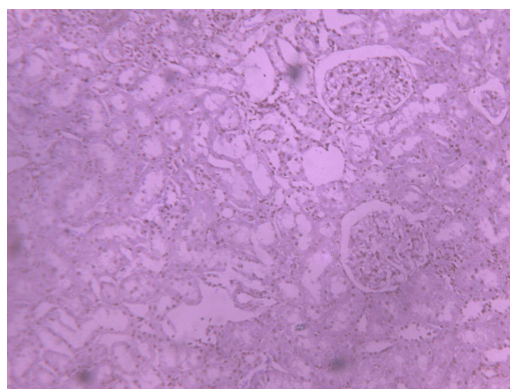


Figure 3e: 60 Days Plant Extract Group

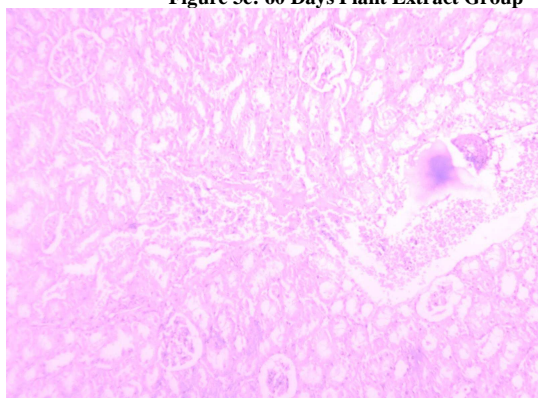
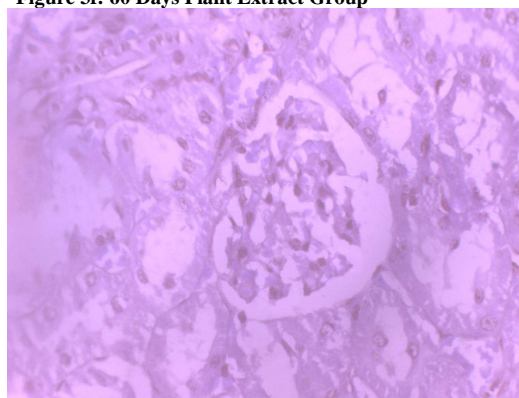
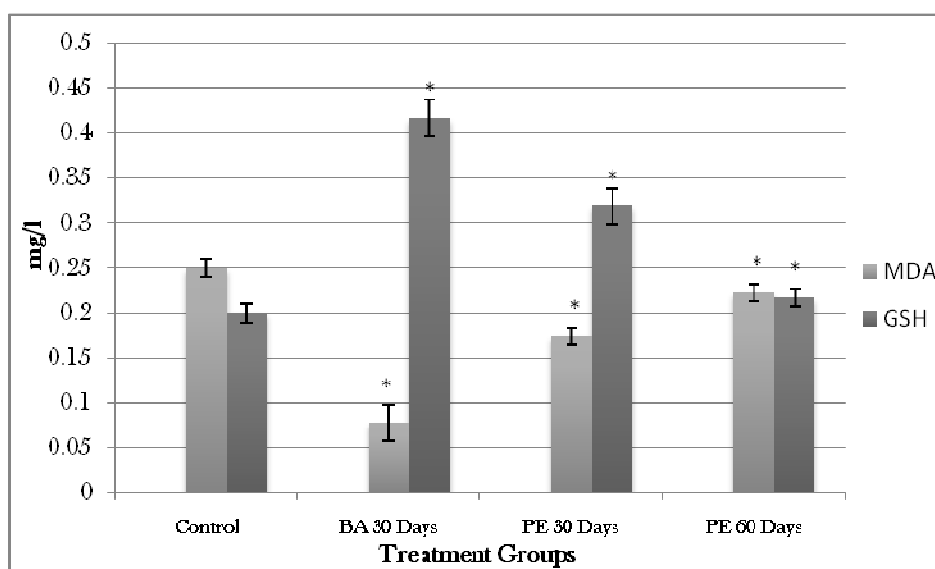


Figure 3f: 60 Days Plant Extract Group



Graph 1: MDA and GSH levels of Testis of Control, following Boric Acid toxicity and plant extract treatment groups.



All values are mean \pm SD for 3 rats. *: $p \leq 0.0001-0.0006$

CONCLUSION

Thus with the treatment of boric acid in rats, the functioning of male reproductive organ is completely hampered and the animals became astheno-necrozoospermic. Boric acid not only affects the testis but also inhibits the functioning of vital organs like liver and kidneys. Thus, the above results reveal that the boric acid induces hepato and nephropathy and is also a potent reproductive toxicant. Following treatment of the boric acid treated animals with the hydroalcoholic plant extract, a reversal in the damaged histoarchitecture of tissue was observed. During the treatment period a decline the oxidative stress was also observed. Reproductive toxicological effect induced by boric acid was also observed to be completely recovered following plant extract treatment. Hence, the extract can be used for the reversal of reproductive toxicity.

Acknowledgement

The authors are grateful for the financial assistance from Nirma Education & Research Foundation (NERF), Ahmedabad for the present investigation. The present investigation is a part the Dissertation Thesis of Ms. Pooja Nair submitted to Nirma University, Ahmedabad.

REFERENCE

- [1] FM Fishel. Ph. D. Thesis, (Florida, USA, **2005**).
- [2] International Programme on Chemical Safety (IPCS). *World Health Organization*, Geneva, **1998**, 192-201.
- [3] DM Creasy. *Toxicologic Pathology*, **2001**, 29(1): 64–76.
- [4] R Fukuda; M Hirode; I Mori; F Chatani; H Morishima and H Mayahara. *The Journal of Toxicological Sciences*, **2000**, 25: 233-239.
- [5] WW Ku; RE Chapin; RN Wine and BC Gladen. *Reproductive Toxicology*, **1993**, 7(4): 305-19.
- [6] A Amin and AA Hamza. *Asian Journal of Andrology*, **2006**, 8(5): 607–612.
- [7] H Chaudhary; V Dhuna; J Singh; SS Kamboj and S Seshadri. *Journal of Ethnopharmacology*, **2011**, 136: 363–367.
- [8] RM Thorat; VM Jadhav; DD Gaikwad and SL Jadhav. *International Research Journal of Pharmacy*, **2010**, 1(1): 77-80.
- [9] World Health Organization. *Laboratory Manual for Examination of Human Semen and Sperm Cervical Mucus Interaction*. New York, Cambridge University Press. **2010**.
- [10] A Zlatkis; B Zak and AJ Boyle. *Journal of Laboratory and Clinical Medicine*, **1953**, 41: 486-492.
- [11] EJ King and IDP Wootton (Eds). *Microanalysis in medical biochemistry*. Churchill Press, London, 3rd Edition, **1956**, 42.
- [12] OH Lowry; DJ Rosenbrought; AL Farr and RJ Randall. *Journal of Biological Chemistry*, **1951**, 193: 265-275.
- [13] M Mihara and M Uchiyama. 1978. *Analytical Biochemistry*, **1978**, 86(1): 271-278.
- [14] E Beutler and MKY Yeh. *Blood*, **1994**, 21: 573-585.
- [15] WG Kempinas and TL Lamasano-Carvalho. *Animals*, **1988**, 22: 154-156.
- [16] RS Jeyendran; HH Vander-Ven; M Perez-Pelaez; BG Crabo and LJ Zaneveld. *Journal of Reproductive Fertility*, **1984**, 70(1): 219-228.
- [17] M Gavella. *Clinical Chemistry*, **1988**, 34(8):1605-1607.
- [18] MJ Lynch; SS Raphael; LD Mellor; PD Spare and MJH Inwood. *Medical Laboratory Technology and Clinical Pathology*, London, WB Saunders Company, **1969**.
- [19] S Natelson. *American Journal of Clinical Pathology*, **1951**, 21: 1153-1172.
- [20] H Wagner; B Geyer; Y Kiso; H Hikino and GS Rao. *Planta Medica*, **1986**, 52: 370-374.
- [21] CP Khare. *Encyclopedia of Indian Medicinal Plants*. Springer-Verlag Berlin Heidelberg, New York, **2004**.
- [22] LD Kapoor. *Handbook of Ayurvedic Medicinal Plants*, (CRC Press LLC), **2001**.
- [23] SA Phadke; and SD Kulkarni. *Indian Journal of Medical Sciences*, **1989**, 43: 113-117.
- [24] A Farouk; A Bashir and A Salih. *Fitoterapia*, **1983**, 54, 3-7.
- [25] Ministry of Health and Family Welfare, Government of India. *The ayurvedic pharmacopoeia of india*, Annual Report, Government of India, 21-25, **2001**.
- [26] E Aysan; F Sahin; D Telci; ME Yalvac; SH Emre; C Karaca and M Muslumanoglu. *International Journal of Medical Science*, **2011**, 8(8): 653-658.
- [27] M Traina; M Rescia; E Urbani; A Mantovani; C Macri; C Ricciardi; A Stazi; P Fazzi; E Cordelli; P Eleuteri; G Leter and M Spano. *Reproductive Toxicology*, **2003**, 17(1): 25-35.
- [28] AM Ronco; K Valdés; D Marcus and M Llanos. *Toxicology*, **2001**, 159(1-2): 99-106.

- [29] M Suwalsky; F Villena; D Marcusand and AM Ronco. *Humens Experimental Toxicology*, **2000**, 19(9): 529-533.
- [30] R. Ananya; S Subeena; DA Kumar; DT Kumar and MS Kumar. *Medical Science Monitor*, **2005**, 11(9): BR325-9.
- [31] P Fail; RE Chapin; CJ Price and JJ Heindel. *Reproductive Toxicology*, **1998**, 12(1): 1-18.
- [32] E Bustos-Obregón; RH Belmar; and R Catriao-Gálvez, R. 2008. *International Journal of Morphology*, **2008**, 26(1): 155-164.
- [33] O Furat; HY Cogun; T Yüzereroğlu; G Gök; F Kargin and Y Kötemen., Y. *Fish Physiology and Biochemistry*, **2011**, 37(3):657-66.
- [34] T. Ichikawa; T Oeda; H Ohmori and WB Schill. *International Journal of Andrology*, **1999**, 2(1): 37-42.
- [35] U Bandyopadhyay; D Das and RK Banerjee. *Current Science*, **1999**, 77: 658-66.
- [36] J Klaunig; Y Xu; J Isenberg; S Bachowski; K Kolaja; J Jiang; D Stevenson; and E Walborg, Jr. *Environmental Health Perspective*, **1998**, 106: 289-295.
- [37] R Rastogi; AL Srivastava and AK Rastogi. *Phytotherapy Research*, **2001**, 15: 307-310.
- [38] SI Grammatikos; PV Subbaiah; TA Victor and WM Miller. *Cytotechnology*, **1994**, 15: 31-50.
- [39] H Turkez and F Geyikoglu. *Cytotechnology*, **2010**, 62(2): 157-165.
- [40] RS Ahmed; SG Suke; V Seth; A Chakraborti; AK Tripathi and BD Banerjee. *Phytotherapy Research*, **2008**, 22(7): 902-906.
- [41] AK Prasad; SC Srivastava; R Kumar and SP Srivastava. *Human Experimental Toxicology*, **1995**, 14(6): 484-488.
- [42] AM Fausto; P Morera; R Margarit; and AR Taddei. *Reproduction Nutrition Development*, **2001**, 41(3): 217-25.
- [43] MV Sawane; SB Kaore; RD Gaikwad; PM Patil; SS Patankar and AM Deshkar. *Indian Journal of Medical Sciences*, **2002**, 56(11): 560-561.
- [44] N Kalla; S Kaur; N Ujwal; U Mehta; H Joos and J Frick. *International Journal of Andrology*, **1997**, 20(2): 92-95.
- [45] CH Yeung and TG Cooper. *Journal of Reproduction and Fertility*, **1994**, 102: 401-410.
- [46] J Guerin; AH Ben; D Cottinet; and J Rollet. *Journal of Andrology*, **1990**, 111(3): 240-245.
- [47] E Sıktar; D Ekinici; E Sıktar; S Beydemir; I Gülçin and M Günay. *European Journal of Pharmacology*, **2011**, 668(3): 407-13.
- [48] JP Infante and VA Huszagh. *Molecular and Cellular Biochemistry*, **1985**, 69(1): 3-6.
- [49] S. Ando; A Carpino; M Buffone; M Maggiolini; C Giacchetto and F. Seidita. *International Journal of Fertility*, **1990**, 35(4): 249-52.
- [50] L Patnaik and AK Patra. *Journal of Applied Science and Environmental Management*, **2006**, 10(3): 5-7.
- [51] T Green; A Toghill; R Lee; F Waechter; E Weber; and J Noakes. *Toxicological Sciences*, **2005**, 86(1): 36-47.
- [52] D Mikhailidis and A Wierzbicki. *Current Medical Research and Opinion*, **2000**, 16(2): 139-146.
- [53] O Mansouri and C Abdennour. *Annals of Biological Research*, **2011**, 2 (3):389-393.
- [54] EM Choi; and JK Hwang. *Phytotherapy Research*, **2005**, 19(5): 382-386.
- [55] R Ge; Q Dong; E Niu; C Sottas; D Hardy; J Catterall; S Latif; D Morris and M Hardy. *Endocrinology*, **2005**, 146(6): 2657-2664.
- [56] RE Chapin and WW Ku. 1994. *Environmental Health Perspective*, **1994**, 102(Suppl 7):87-91.
- [57] EM Abdel-Magied; HA Abdel-Rahman; and FM Harraz, F.M. *Journal of Ethnopharmacology*, **2001**, 75(1): 1-4.
- [58] PB Udoh; FV Udoh; EB Umoren; UW James; CP Okeke and A Agwu. *Nigerian Journal of Physiological Sciences*, **2009**, 24(1):13-15.