Available online at www.scholarsresearchlibrary.com

Scholars Research Library

***J. Nat. Prod. Plant Resour.*, 2011, 1 (1): 46-56**
(http://scholarsresearchlibrary.com/archive.html)

Evaluation of *Argemone mexicana* Linn. Leaves for wound healing activity

G. K. Dash*[1] and P. N. Murthy[2]

[1]*Institute of Pharmacy and Technology, Salipur, Cuttack district, Odisha, India*
[2]*Royal College of Pharmacy and Health Sciences, Berhampur, Odisha, India*

ABSTRACT

The petroleum ether, chloroform, methanol and aqueous extracts of the leaves of Argemone mexicana Linn. (Family: Papaveraceae) were evaluated for their wound healing activity in rats using excision (normal and infected), incision and dead space wound models respectively. The effects of test samples on the rate of wound healing were assessed by the rate of wound closure, period of epithelialisation, wound breaking strength, weights of the granulation tissue, determination of hydroxyproline, super oxide dismutase (SOD), catalase and histopathology of the granulation tissues. Nitrofurazone (0.2% w/w) in Simple ointment I. P. was used as reference standard for the activity comparison. The results of the study revealed that the animals treated with methanol and aqueous extracts of A. mexicana showed faster rate of wound healing compared to other extracts under study. The chloroform extract of the selected plants also produced promising results but the effects are seen to be of lesser extent than the corresponding methanol and aqueous extracts. The petroleum ether extract did not produce significant results. The wound healing effects of the chloroform, methanol and aqueous extracts may be attributed to the presence of phytoconstituents like alkaloids, triterpenoids, tannins and flavonoids in the extracts which are known to promote the wound healing process mainly due to their astringent, antioxidant and antimicrobial properties. The present work justifies the use of the leaves of A. mexicana for wound healing activity as claimed in the folklore literature.

Key words: *Argemone mexicana* Linn.; Wound healing; Excision wound model; Incision wound model; Dead space wound model.

INTRODUCTION

Argemone mexicana Linn. (Family: Papaveraceae) is a prickly, glabrous, branching annual herb with yellow juice and showy yellow flowers, naturalized throughout up to an altitude of 1500 m. It occurs as wasteland weed in almost every part of India [1-3].

Traditionally, the plant is reported to be used as diuretic, purgative, anti-inflammatory, analgesic and believed to destroy worms, cure itching, various skin diseases and an antidote to various poisons [4]. The seeds are purgative and sedative (Ayurveda) [3], useful in skin diseases and leucoderma (Yunani) [2] and in Homeopathy, the tincture of the entire plant is

reported to be used orally for bronchitis and whooping cough [5, 6]. The fresh juice of the leaves and the latex, both are reported to be used externally as a disinfectant for open wounds and cuts [7-12].

Several isoquinoline alkaloids viz. cheilanthifoline, berberine, coptisine, cryptopine, muramine, protopine, scoulerine, sanguinarine, stylopine and thalifoline have been reported from the plant [13-18].

Reports on the biological activities are many. The alkaloid sanguinarine has been reported to prolong ventricular refractoriness and this property may be useful in treatment of ventricular arrhythmias. The ethanol extract of the entire plant is reported to possess antiviral, hypotensive and smooth muscle stimulant activity [19-21] and found to be active against *Proteus vulgaris, Sarcina lutea, Staphylococcus aureus, Candida albicans, Escherichia coli, Pseudomonas aeruginosa, Salmonella newport, Shigella flexneri, Staphylococcus albus* and *Serratia marcescens* [20, 22]. Aqueous extract of leaves have been reported to possess anti-inflammatory activity [23]. The alkaloid fractions of the roots are reported to possess antiinflammatory activity [24] and strong uterine stimulant effect [25].

The present paper deals with the wound healing activity of the leaves on standard animal models.

MATERIALS AND METHODS

Plant material and extraction

Fresh leaves were collected from young matured trees and authenticated by the taxonomists of the Botanical Survey of India, Shibpur, Howrah. After authentication, the plant materials were collected in bulk, washed under running tap water to remove adhering dirt followed by rinsing with distilled water. The plant material was then shade dried and pulverized in a mechanical grinder followed by sieving (sieve no. 40) to obtain coarse powder. The powdered leaves (500 g) was successively extracted with petroleum ether (40-60^0 C), chloroform, methanol and water for 48 h in a soxhlet extractor. Following extraction, the liquid extracts were concentrated under vacuum to yield dry extracts. Standard methods [26, 27] were used for preliminary phytochemical screening of the different extracts to know the nature of phytoconstituents present within them (Table 1).

Animals

Healthy Wistar albino rats (150–250 g) of either sex and of approximately the same age were used for the study. They were individually housed, maintained in clean polypropylene cages and fed with commercially pellet diet (M/s Hindustan Lever Ltd., Mumbai) and water *ad libitum*. The experimental protocols were subjected to scrutiny of Institutional Animal Ethics Committee for experimental clearance (No. 1025/C/07/CPCSEA).

Wound healing activity

The selected extracts of *A. mexicana* were separately evaluated for their wound healing activity in rats using excision (normal and infected), incision and dead space wound models. The effects of test samples on the rate of wound healing were assessed by the rate of wound closure, period of epithelialisation, wound breaking strength, weights of the granulation tissue, determination of hydroxyproline, super oxide dismutase (SOD), catalase and histopathology of the granulation tissue. Nitrofurazone (0.2% w/w) in Simple ointment I. P. was used as reference standard for the activity comparison. The test extracts were mixed with Simple ointment I. P. (10% w/w) and

used in the excision and incision models. For the dead space wound model, the methanol extract was suspended in water and used.

Excision Wound Model (Normal wounds)

Animals were anesthetized prior to and during creation of the wounds, with 1 ml of intravenous ketamine hydrochloride (10 mg/kg). The rats were inflicted with excision wounds as described by Morton and Malone [28] and suggested by Kamath *et al.* [29]. An impression was made on the dorsal thoracic region 1 cm away from vertebral column and 5 cm away from ear on the anaesthetized rat. The dorsal fur of the animals was shaved with an electric clipper and the anticipated area of the wound to be created was outlined on the back of the animals with methylene blue using a circular stainless steel stencil. A full thickness of the excision wound of circular area of 500 mm^2 and 2 mm depth was created along the markings using toothed forceps, scalpel and pointed scissors. Haemostasis was achieved by blotting the wound with cotton swab soaked in normal saline. The entire wound was left open [30]. All surgical procedures were performed under aseptic conditions.

The control group animals (Group I) were treated with the vehicle (Simple ointment I. P.), the positive control (Group II) was applied with 0.2% w/w nitrofurazone in Simple ointment I. P. Other groups of animals were treated with the following: petroleum ether, chloroform, methanol or aqueous extracts of *A. mexicana* at a concentration of 10% w/w in Simple ointment I. P. in a similar manner.

The wound closure rate was assessed by tracing the wound on days 1, 4, 6, 8, 11, 14 and 16 post wounding days using transparent paper and a permanent marker. The wound areas recorded were measured using graph paper [31]. The percentage of wound healing was calculated of original wound size for each animal of group on predetermined days i.e. 1, 4, 6, 8, 11, 14 and 16 days post-wounding for final analysis of results. Changes in wound area were calculated, giving an indication of the rate of wound contraction [32]. The period of epithelialisation was calculated as the number of days required for falling of the dead tissue remnants without any residual raw wound. The results are tabulated in Table 2.

Incision Wound Model

The rats were anaesthetized prior to and during creation of the wounds, with 1 ml of intravenous ketamine hydrochloride (10 mg/kg). The dorsal fur of the animals was shaved with an electric clipper. A longitudinal paravertebral incision of 6 cm long was made through the skin and cutaneous tissue on the back as described by Ehrlich and Hunt [33]. After the incision, the parted skin was sutured 1 cm apart using a surgical thread and curved needle. The wounds were left undressed [34]. Extracts were topically applied to the wound once a day. The sutures were removed on 8th post wound day and continued the application of the extract. The wound breaking strength [35] was measured on the 10th day evening after the last application. The results are tabulated in Table 3.

Excision Wound Model (Infected wounds)

The results of the excision and incision wound models revealed that the methanol extract of *A. mexicana* possess comparatively better wound healing activity compared to other test extracts under study. Therefore, infected wound model was separately performed on the methanol extract of *A. mexicana* taking *Staphylococcus aureus* and *Pseudomonas aeruginosa* as the infecting bacteria.

The methods of *Abo et al*., 2004 [36] was followed. The selected rats were divided into three groups, each containing 6 animals. A round seal of 20 mm diameter was impressed on the two sides of the central trunk depilated and sterilized with ethanol. Excision wound was inflicted on the rats as described earlier. Full skin thickness was excised from the marked area to get a wound measuring about 314 mm^2. After achieving complete haemostasis by blotting the wound with cotton swab soaked in warm saline, the wound of each animal was inoculated separately with an overnight (18 h old) *S. aureus* and *P. aeruginosa* cultures. The animals were placed singly in individual cages. The infected wounds on each animal of the control group were treated topically with Simple ointment I. P. Other groups of animals were treated separately with one of the following: 0.2% w/w nitrofurazone or 10% w/w methanol extract of *A. mexicana* in Simple ointment I. P. in a similar manner.

Treatments of the infected wounds commenced on the 3rd day to allow for the establishment of the infection on the wound. The wound area was measured with a transparent graph paper on 1, 4, 6, 8, 11, 14 and 16 day. Wound contraction was calculated as a percentage of the original wound size. The results are presented in Table 4 and 5.

Acute oral toxicity studies

Acute oral toxicity studies of the extracts were carried out as per the OECD guidelines, draft guidelines 423 [37]. Different groups of animals each containing three female rats (180–210 g) received *A. mexicana* methanol extract suspended in water separately at doses of 300, 600 and 2000 mg/kg orally by gavage. Animals were observed individually after dosing once during the first 30 minutes, periodically during the first 24 hours, with special attention given during the first 4 hours and daily thereafter, for a total of 14 days. Observations included changes in skin and fur, eyes and mucous membranes, respiratory and behaviour pattern. A special attention was directed to observations of tremors, convulsions, salivation, diarrhea, lethargy, sleep and coma. The change in body weight, food and water intake was recorded at two days interval.

There was no mortality or morbidity observed in animals through the 14-day period following single oral administration at all selected dose levels of the methanol extract of *A. mexicana*. Morphological characteristics (fur, skin, eyes and nose) appeared normal. No tremors, convulsion, salivation, diarrhea, lethargy or unusual behaviours such as self mutilation, walking backward and so forth were observed; gait and posture, reactivity to handling or sensory stimuli, grip strength were all normal. There was no significant difference in body weights between control and treatment groups.

Dead space Wound Model

Dead space wounds were created by implanting two pre-weighed sterilized polypropylene tube (2.5 length x 0.25 cm diameter) beneath the dorsal para-vertebral skin of the anaesthetized rats [38]. The animals were randomly divided into two groups of six each. The control group animals were provided with plain drinking water and the other group rats were separately administered with the methanol extract of *A. mexicana* at a dose of 100 mg/kg daily. On the 10th post wounding day, the granulation tissue formed on the implanted tubes was carefully detached from surfaces of the tubes. The wet weight of the granulation tissue collected was noted. The tissue samples were dried at 60° C for 12 h and weighed to determine the dry granulation tissue weight. The results are depicted in Table 6.

The dried tissue (50 mg) was added to 1 ml 6 M HCl and kept at 110° C for 24 h. The neutralized acid hydrolysate of the dry tissue was used for the determination of

hydroxyproline [39]. Part of the granulation tissue was collected in phosphate-buffered saline for the estimation of antioxidant enzymes superoxide dismutase (SOD) [40] and catalase [41].

Histological studies

For histological studies, pieces of granulation tissues from dead space wound model were fixed in 10% neutral formalin solution for 24 h and dehydrated with a sequence of ethanol-xylene series of solutions. The materials were filtered and embedded with paraffin (40-60 °C). Microtome sections were taken at 10 µ thickness. The sections were processed in alcohol-xylene series and stained with hemotoxylin-eosin dye. The histological changes were observed under a microscope. Photographs were taken from each slide and presented in Fig. 1.

Statistical Analysis

The data obtained in the studies were subjected to one way of analysis of variance (ANOVA) for determining the significant difference. The inter group significance was analyzed using Dunnet's t-test. A p-value <0.05 was considered to be significant. All the values were expressed as Mean ± SEM.

RESULTS AND DISCUSSION

The preliminary phytochemical screening of *A. mexicana* leaf extracts showed presence of steroids and sterols, triterpenoids, alkaloids, flavonoids, saponins, tannins and phenolic substances, gums and mucilages, carbohydrates and proteins respectively in different extracts (Table 1).

In both the models studied (Excision and incision), significantly improved wound-healing activity has been observed with the chloroform, methanol and aqueous extracts of *A. mexicana* compared to that of the reference standard and control group of animals. In the excision wound model, the chloroform extract showed significant percentage closure of wounds from 14th day ($p<0.05$) and the aqueous extract from 8th day of the study, but the methanol extract registered significant percentage wound closure from 6th day with 100% closure on 16th day. The methanol extract treated animals showed faster rate of epithialisation (16.0 ± 0.97) compared to all the extracts under study (Table 2).

Table 3 depicts the wound healing effect of *A. mexicana* in the incision wound model. In this model, the methanol and aqueous extract treated animals demonstrated significant ($p<0.01$) skin-breaking strength up to 480.88 ± 7.12 and 404.16 ± 11.82 respectively when compared to control animals (327.5 ± 16.58). The animals treated with the chloroform extract also revealed significant increase ($p<0.05$) in breaking strength. The petroleum ether extract however did not elicit significant response. Hence, we can infer that the methanol extract not only is actively promoting faster wound contraction, but also acting as potent agent in aiding the process of tissue granulation and remodeling in the first week of the healing process where as second week for the chloroform and aqueous extracts.

In the infected wound model (Table 4), the methanol extract showed significant healing effect against *S. aureus* inoculated wounds right from 6th day and throughout the study with a comparable activity to that of the reference standard. The methanol extract registered 91.33 ± 3.28 percentage wound closure as against nitrofurazone with 97.33±1.97 wound closure effect on the 16th day of the study. In *P. aeruginosa* inoculated wounds, the methanol extract however registered significant healing effects from 8th day and continued up to 16th day. The period of epithelialization was 22.14 ± 0.81 days (Table 5).

Table 1: Preliminary phytochemical screening of different extracts of *A. mexicana* leaves

Extract	Alkaloids	Carbohydrates	Glycosides	Gums and mucilages	Proteins and amino acids	Tannins and phenolic compounds	Steroids and sterols	Triterpenoids	Saponins	Flavonoids
Pet. Ether	-	-	-	-	-	-	+	+	-	-
Chloroform	+	-	-	-	-	-	+	+	-	-
Methanol	+	-	-	-	-	+	-	-	+	+
Aqueous	-	+	-	+	+	+	-	-	+	+

(+): Present; (-): Absent.

Table 2: Effect of various extracts of *A. mexicana* leaves on percentage (%) wound closure (Excision Wound Model)

Group	Treatment	Concentration	Percentage (%) wound closure.						Period of epithelialization (No. of days)
			4th days	6th days	8th days	11th days	14th days	16th days	
I	Control	-	23.52±1.21	37.72±1.58	51.92±1.71	71.28±2.23	79.24±1.18	83.56±1.03	23.16±0.71
II	Nitrofurazone	0.2% w/w	48.53±2.87*	74.23±3.32**	84.8±1.26**	96.54±1.29**	100±00**	-	13.5±1.54**
III	Pet ether extract	10% w/w	22.47±1.49	41.47±1.54	56.83±2.66	71.72±1.2	82.72±2.21	83.4±2.21	20.33±1.25
IV	Chloroform extract	10% w/w	24.75±1.32	43.35±1.26	58.82±2.07	73.51±2.44	84.76±1.19*	88.36±0.97*	19.16±0.88*
V	Methanol extract	10% w/w	29.2±1.56	45.96±2.27*	67.35±2.91**	86.37±1.55**	96.1±1.03**	100±00**	16±0.97**
VI	Aqueous Extract	10% w/w	27.69±1.57	43.97±1.45	63.24±1.39*	79.18±1.12*	93.51±1.45**	95.16±1.18**	17.5±0.78**

*Values are expressed as mean ±S.E. (n = 6). All columns are significant using ANOVA, * P<0.05, ** P<0.01 when compared to control; Dunnet's t-test.*

Table 3*:* Effect of various extracts of *A. mexicana* leaves on wound breaking strength (Incision Wound Model)

Group	Treatment	Breaking strength (g)
I	Control	327.5±16.58
II	Nitrofurazone (0.2% w/w)	491.21±16.26**
III	Pet ether extract	343.16±10.44
IV	Chloroform extract	388.66±13.18*
V	Methanol extract	480.88±7.12**
VI	Aqueous Extract	404.16±11.82**

Values are expressed as mean ±S.E. (n = 6). All columns are significant using ANOVA.
** P<0.05, ** P<0.01 when compared to control; Dunnet's t-test.*

In dead space wound model (Table 6), the methanol extract treated animals showed significant increase in dry weight of granulation tissue. Estimation of hydroxyproline content in the granulation tissue revealed higher concentration of hydroxyproline in methanol extract treated group (7600.00 ± 669.33). SOD and catalase level in the granulation tissue was significantly increased in the case of rats treated with the methanolic extract ($P < 0.01$) when compared with control.

Histological studies of the tissue obtained from the methanol extract treated [Fig.-1 (e)] group showed significant increase in collagen deposition, few macrophages, tissue edema and more fibroblasts. It was more or less equal to the animals treated with nitrofurazone [Fig.-1 (b)]. The aqueous extract [Fig.-1 (f)] treated group of animals showed similar kind of effect but to a lesser extent. The chloroform extract [Fig.-1 (d)] treated group of animals showed lesser collagen fiber. The histological studies of the granulation tissue of the control group of animals [Fig.-1 (a)] and petroleum ether treated groups [Fig.-1 (c)] showed more aggregation of macrophages with lesser collagen fiber. The wound healing was more significant in the methanol extract treated group of animals than the other extracts under study.

The results of the present study revealed that, animals treated with methanol and aqueous extracts of *A. mexicana* showed faster rate of epithelialization in excision wound model compared to other extracts under study. The chloroform extract of the selected plants also produced promising results but the effects are seen to be of lesser extent than the corresponding methanol and aqueous extracts. The petroleum ether extract of all the plant materials did not produce significant results. The wound healing effects of the chloroform, methanol and aqueous extracts may be attributed to the presence of phytoconstituents like alkaloids, triterpenoids, tannins and flavonoids in the extracts which are known to promote the wound healing process mainly due to their antimicrobial property. Flavonoids and triterpenoids are also known to promote the wound-healing process mainly due to their astringent and antimicrobial property, which seems to be responsible for wound contraction and increased rate of epithelialisation [42-44]. In the present laboratory all the surgical interventions were carried out under sterile conditions and animals were closely observed for any infection; those which showed signs of infection were separated and excluded from the study. This is very important and researchers proved that the control microbial infection is necessary for better wound healing and its management [45, 46].

Table 4: Screening for wound healing activity of the methanol extract of *A. mexicana* (Excision Wound inoculated with *Stapphylococcus aureus*)

Group	Treatment	Dose	Percentage (%) wound closure.						Period of epithelialization (No. of days)
			4th days	6th days	8th days	11th days	14th days	16th days	
I	Control	ml/kg	10±1.29	19.5±2.34	34±3.83	44.5±5.75	52±4.53	58.4±5.85	29.12±2.65
II	Nitrofurazone (0.2% w/w)	mg/kg	15.83±6.21	36.33±2.98**	59.5±4.48**	76.33±4.91**	90.5±3.39**	97.33±1.97**	18.03±1.23**
III	Methanol extract (AM)	mg/kg	14.66±1.6	31.33±2.62*	51±2.65*	67±2.2**	75.61±2.59**	91.33±3.28**	20.26±0.71*

*Values are expressed as mean ±S.E. (n = 6). All columns are significant using ANOVA. * P<0.05, ** P<0.01 when compared to control; Dunnet's t-test. AM - A. mexicana.*

Table 5: Screening for wound healing activity of the methanol extract of *A. mexicana* (Excision Wound inoculated with *Pseudomonas aeruginosa*)

Group	Treatment	Dose	Percentage (%) wound closure.						Period of epithelialization (No. of days)
			4th days	6th days	8th days	11th days	14th days	16th days	
I	Control	ml/kg	8.22±1.81	15.6±1.22	21.08±2.71	32.41±3.33	46.61±3.85	51.13±2.15	30.33±2.23
II	Nitrofurazone (0.2% w/w)	mg/kg	14.21±1.09	25.73±3.81*	39.43±2.22**	57.63±3.11**	78.56±2.48**	92.53±3.25**	18.73±1.81**
III	Methanol extract (AM)	mg/kg	10.31±1.87	17.23±2.91	30.01±2.25*	41.5±3.2*	63.81±2.8**	81.23±3.68**	22.14±0.81*

*Values are expressed as mean ±S.E. (n = 6). All columns are significant using ANOVA. * P<0.05, ** P<0.01 when compared to control; Dunnet's t-test. AM - A. mexicana*

Table 6. Wound healing effects of the methanol extracts of *A. mexicana* in Dead Space Wound Model, Hydroxyproline content in granulation tissues and the level of antioxidant enzymes in granuloma tissue.

Treatment	Wet tissue weight (mg)	Dry tissue weight (mg)	Concentration of hydroxyproline (mg/100 g dry tissue)	Superoxide dismutase (units/mg)	Catalase (unit/mg)
Control	91.36 ± 2.37	42.22±2.07	2933.33±326.60	0.117±0.011	0.08±0.013
Methanol extract (AM)	111.33±4.55**	65.83±3.52**	7600.00±669.33**	0.182±0.022*	0.41±0.011*

*Values are expressed as mean ±S.E. (n = 6). * P<0.05, ** P<0.01 when compared to control; Dunnet's t-test. (AM – A.mexicana).*

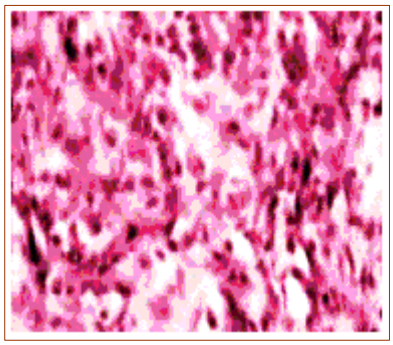

Fig- 1 (a): Granulation tissue of group I animal (control) showing with less collagen and more macrophages.

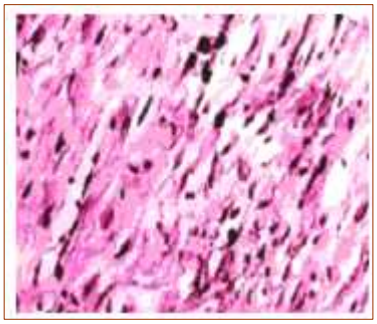

Fig- 1 (b): Granulation tissue of group II (standard) animal showing significant collagenation, lesser fibroblasts and capillaries.

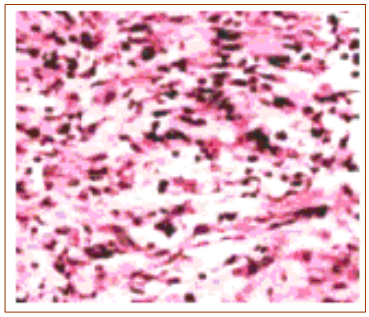

Fig- 1 (c): Section of granulation tissue of group III animal (pet-ether extract) showing with less collagenation with less monocytes and fibroblasts and capillaries.

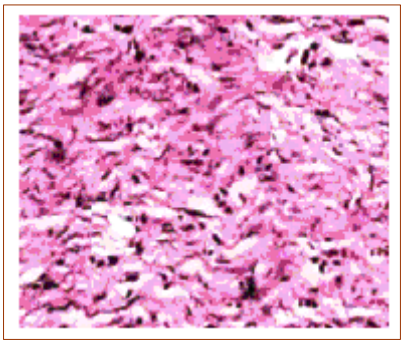

Fig- 1 (d): Granulation tissue of group IV (chloroform extract) animal showing with less collagen and moderate macrophages.

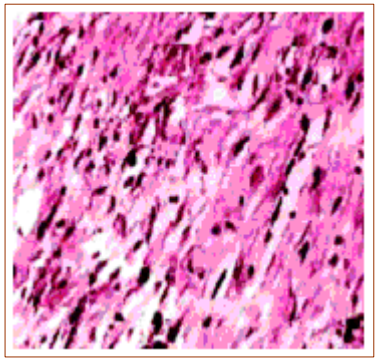

Fig- 1 (e): Histological section of granulation tissue of group V animal treated with methanol extract showing significant increased collagenation, few macrophages and capillaries.

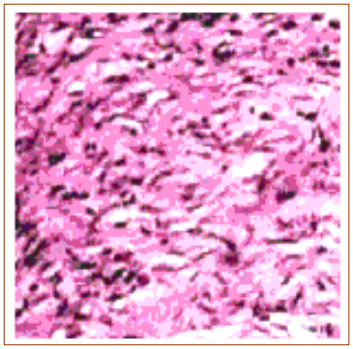

Fig- 1 (f): Section of granulation tissue of group VI (aqueous extract) animal showing moderate collagenation with less macrophages and fibroblasts, and capillaries.

Fig. 1: Histology of granulation tissue of *A. mexicana*

Increase in skin breaking strength and tissue breaking strength in incision and dead space wound model respectively indicated enhanced collagen maturation. Increase in the granulation tissue dry weight and hydroxyproline content indicated the high collagen turnover which may be due to the activity of some phytoconstituents like flavonoids which are known to reduce lipid peroxidation not only by preventing or slowing the onset of cell necrosis but also by improving vascularity. Hence, any drug that inhibits lipid peroxidation is believed to increase the viability of collagen

fibrils by increasing the strength of collagen fibers, by increasing the circulation, by preventing the cell damage and by promoting the DNA synthesis [47]. Hence, the wound healing promoting activity of *A. mexicana* may also be attributed to the antioxidant and antibacterial potency of the active constituents present in them.

Thus, wound-healing property of the methanol and aqueous extracts may be attributed to the phytoconstituents they contain, which may be either due to their individual or additive effect that fastens the process of wound healing. The methanol extracts of each selected plant materials were found to possess better wound-healing property over other extracts. At this stage, it is difficult to say which component(s) of the extracts are responsible for the wound healing activity. However, further phytochemical studies are needed to isolate the active compound(s) responsible for these pharmacological activities.

REFERENCES

[1] A. Mukherjee, D. Namhata. *Ethnobotany*, **1990**, l (2), 57-60.
[2] H. N. Chaudhuri Rai, D. C. Pal, C. R. Tarafdar, *Bull. Bot. Surv. India*, **1985**, 17, 132-136.
[3] P. K. Das, M. K. Mishra, *Indian J. For.* **1987**, 10 (4), 301-303.
[4] A. B. Prusti, A. Mishra, *Plant Sci. Res.*, **2005**, 27 (1&2), 16-23.
[5] J. Eldridge, *Econ. Bot.* **1995**, 29, 307-332.
[6] C. P. Kala, *J. Ethnobiol. Ethnomed.*, **2005**, 1, 11.
[7] R. D. Girach, Aminuddin, P. A. Siddioui, S. A. Khan *Int. J. Pharmacog.*, **1994**, 32(3), 274-283.
[8] V. K. Singh, Z. A. Ali, S. T. H. Zaidi, *Fitoterapia* **1996**, 67(2), 129-139.
[9] R. Prasad, S. K. Verma, R. Dua, S. Kant, R. A. S. Kushwaha, S. P. Agarwal, *Lung India*, **2009**, 26(3), 70–73.
[10] M. Panghal, V. Arya, S. Yadav, S. Kumar, *J. Ethnobiol. Ethnomed.*, **2010**, 6, 4.
[11] C. Alagesaboopathi, *Afr. J. Tradit. Complement. Altern. Med.*, **2009**, 6(3), 222–227.
[12] D. P. Kisangau, H. V. M. Lyaruu, M. H. Ken, C. C. Joseph, *J. Ethnobiol. Ethnomed.*, **2007**, 3, 29.
[13] I. A. Israilov, M. S. Yunusov, *Chem. Nat. Comp.* **1986**, 22(2), 189-192.
[14] B. Dinda, J. Bandyopadhyay, *J. Indian Chem. Soc.*, **1986**, 63(10), 934-936.
[15] A. C. Santos, P. Adkilen, *J. Amer. Chem. Soc.*, **1932**, 54, 2923.
[16] B. T. Yu, D. A. Murav'eva, *Rast. Resur.* **1973**, 9, 200.
[17] K. Haisova, J. Slavik, *Collect. Czech. Chem. Commun.* **1975**, 40, 1576.
[18] R. S. Gupta, V. P. Dixit, M. P. Dobhal, *Fitoterapia* **1990**, 61(1), 67-71.
[19] P. Víctor, F. García, R. Valdés, J. C. Martín, J. H. Ayala, *J. Biomed. Biotechnol.*, **2006**, 6(3), 518.
[20] P. C. Feng, L. J. Haynes, K. E. Magnus, J. R. Plimmer, H. A. S. Sherrat, *J. Pharm. Pharmacol.*, **1962**, 14, 556-561.
[21] M. Goto, T. Noguchi, T. Watanabe, I. Ishikawa, M. Komatsu, Y. Aramaki, *Takeda Kenkyusho Nempo*, **1957**, 16, 21.
[22] M. A. Zavala, S. Perez, R. M. Perez, *Phytother. Res.*, **1997**, 11(5), 368-371.
[23] A. Asthana, H. V. Mall, K. Dixit, S. Gupta, *Int. J. Crude Drug Res.*, **2001**, 27(1), 25-58.
[24] E. Quisumbing, *Agr. Nat. Resources*, **1951**, 1, 1.
[25] B. T. Yu, S. D. Sokolov, *Patol. Fiziol. Ekspter.* **1973**, 17, 57-59.
[26] J. B. Harborne, *Phytochemical Methods: A Guide to Modern techniques of Plant analysis*. Chapman and Hall, New York, **1984**, 37-214.
[27] H. Wagner, S. Bladt, *Plant Drug Analysis*. Springer-Verlag Berlin Heidelberg, Germany, **1996**, 3-335.
[28] J. J. Morton, M. H. Malone, *Arch. Int. Pharmacodyn. Ther.*, **1972**, 196, 117-120.

[29] J. V. Kamath, A. C. Rana, A. R. Chowdhury, *Phytother. Res.*, **2003**, 17, 970-972.
[30] O. H. Lowry, N. J. Rosenbrough, A. L. Farr, B. J. Randall, *J. Biol. Chem.*, **1951**, 193, 265-275.
[31] S. V. Fulzele, P. M. Satturwar, S. B. Joshi, A. K. Dorle, *Ind. J. Pharm. Sci.*, **2003**, 65(3), 301-304.
[32] H. P. Ehrlich, T. K. Hunt, *Ann. Surg.*, **1968**, 167, 324-328.
[33] H. P. Ehrlich, T. K. Hunt, *Ann. Surg.*, **1969**, 170, 203–208.
[34] K. H. Lee, *J. Pharmacol. Sci.*, **1968**, 57, 1238–1240.
[35] J. S. Reddy, P. R. Rao, M. S. Reddy, *J. Ethnopharmacol.*, **2002**, 79, 249–251.
[36] A. Abo, J. A. O. Olugbuyiro, S. A. Famakinde, *Afr. J. Biomed. Res.*, **2004**, 7, 85–87.
[37] Anonymous. *OECD Guidelines for the testing of chemicals, revised draft guidelines 423: Acute Oral toxicity- Acute toxic class method, revised document*. 2000. CPCSEA, Ministry of Social Justice and Empowerment, Govt. of India.
[38] K. Ilango, V. Chitra, *Trop. J. Pharm. Res*., **2010**, 9 (3), 223-230.
[39] R. E. Neuman, M. A. Logan, *J. Biol. Chem.*, **1950**, 184(1), 299-306.
[40] H. P. Mishra, I. Fridovich, *J. Biol. Chem.*, **1972**, 247, 3170-3175.
[41] H. E. Aebi, *Methods of Enzymatic Analysis.* Academic Press, New York, **1974**, 273–284.
[42] C. Ya, S. H. Gaffney, T. H. Lilley, E. Haslam, *Chemistry and significance of condensed tannins*. Plenum Press, New York, **1988**, 553.
[43] H. Tsuchiya, M. Sato, T. Miyazaki, S. Fujiwara, S. Tanigaki, M. Ohyama, T. Tanaka, M. Iinuma, *J. Ethnopharmacol.*, **1996**, 50, 27-34.
[44] M. Scortichini, M. P. Rossi, *J. Appl. Bacteriol.*, **1991**, 71, 109-112.
[45] S. Levine, *J. Am. Podiatry Assoc.*, **1970**, 60, 486-487.
[46] H. S. Muhammad, S. Muhammad, *Afr. J. Biotech.*, **2005**, 4, 934-937.
[47] M. Getie, M. T. Gebre, R. Reitz, R. H. Neubert, *Pharmazie*, **2002**, 57: 320-322.