



Scholars Research Library

Der Pharmacia Lettre, 2014, 6 (6):122-128
(<http://scholarsresearchlibrary.com/archive.html>)



Hepatoprotective and antioxidant effect of *Gynocardia odorata roxb* against acetaminophen induced hepatotoxicity in rats

Mani Rupeshkumar¹, Kunchu Kavitha¹ and Pallab Kanti Haldar^{2,*}

¹East Point College of Pharmacy, Bidarahalli, Bangalore, Karnataka, India

²Department of Pharmaceutical Technology, Jadavpur University, Kolkata, West Bengal, India

ABSTRACT

In the present study the methanol extract of *Gynocardia odorata roxb* (MEGO) against acetaminophen induced hepatotoxicity and anti-oxidant activity in Wistar albino rats was analysed. The methanol extract of *G.odorata roxb* (200, and 400 mg/kg body weight) was administered orally to two groups of rats (six animals per group) in order to evaluate the protective effect of the extract in rats. The other three groups were received normal saline (2 ml/kg), acetaminophen (750 mg/kg), and silymarin (50 mg/kg) respectively. The anti-oxidant effect of the extract on serum marker enzymes and histopathological studies of liver was assessed. The plant extract (200 and 400 mg/kg, p.o.) showed a remarkable hepatoprotective and antioxidant activity against acetaminophen induced hepatotoxicity. Histopathological changes of liver sample shows mild hepatocyte degeneration. Results indicate that the *G.odorata roxb* possesses significant hepatoprotective and antioxidant property. Thus the study substantiates its use in traditional herbal medicine.

Key words: *Gynocardia odorata roxb*, Acetaminophen, Biochemical parameters, Antioxidants, Histopathology.

INTRODUCTION

Herbal medication plays a major role in the treatment of hepatic disorders. In the absence of reliable liver protective drugs in trendy medication, in India, variety of medicinal plants and their formulations are accustomed to cure hepatic disorders in traditional systems of medication [1]. Many studies were conducted in the field of drug discovery and development but due to the side effects of contemporary medication, natural remedies are considered to be effective and safe alternate treatments for hepatotoxicity.

Cellular oxidants referred to as reactive oxygen species (ROS), which are created in animal and human biological system, are responsible for oxidative damage in cell constituents thus producing numerous chronic diseases and aging. This oxidative modification promotes age-related disorders, including cardiovascular diseases. Such damages in human biological system are prevented by cellular antioxidants. Antioxidant-based drugs are known to prevent various diseases like atherosclerosis, stroke, diabetes, Alzheimer's disease, and cancer [2-4]. Various macromolecules like proteins, DNA, and lipids are damaged by free radicals and actions of radicals are opposed by antioxidants by suppressing their formation or by scavenging them [5].

Gynocardia odorata roxb is also known as Chaulmoogra plant belongs to the family of Flacourtiaceae, which is indigenous to parts of India, Malaysia and tropical countries of the world contain fatty acids chaulmoogric acid, hydnocarpic acid. Chaulmoogra oil is an important therapeutic agent in certain medical traditions [6]. The seeds of *G.odorata roxb* are most commonly used. The fruits are hot anthelmintic and used in bronchitis, skin diseases, small tumor's leprosy, and as an analgesic. *G.odorata roxb* is reported to contain antioxidant properties [7]. *G.odorata roxb* may have its antiulcer activity because of its active constituents like flavonoids and especially quercetin [8-9]. It was reported that *G.odorata roxb* could be a natural medication alternative of thrombolytic agents as well as

source of potent bioactive compounds [10]. These activities have been already reported but anti-diabetic activity is not established yet. In the present study we made an attempt to establish the hepatoprotective potential of methanol leaf extracts of *G.odorata roxb*.

MATERIALS AND METHODS

Drugs and chemicals

Silymarin was purchased from Micro Labs, India, 1-chloro-2,4-dinitrobenzoic acid (CDNB), 5,5-dithiobis (2-nitrobenzoic acid) (DTNB), Reduced glutathione (GSH) and glutathione were purchased from Sisco Research Laboratories Pvt. Ltd., Mumbai, India. Thiobarbuturic acid was purchased from E- Merck, India. All other chemical used were of analytical grade.

Collection and extraction

The fresh leaves of *Gynocardia odorata roxb* were collected from the Authenticated crude drug supplier in Delhi and authentication of the plant was carried in Botanical Survey of India, Coimbatore, India. A voucher specimen has been deposited in the laboratory for future reference (BSI/SC/7/46/13-14/TECH.785).

The leaves of the plant were shade dried and pulverized. The powder was defatted with petroleum ether. Later, it had been subjected to continuous hot extraction with 95% aqueous methanol in a Soxhlet apparatus. The extract (MEGO) was concentrated under vacuum and dried in desiccators (yield 69gm, 6.9% w/w). The dry extract was kept in vacuum desiccators until use. Preliminary phytochemical analysis [11] revealed the presence of flavonoids, alkaloids, and steroids in MEGO Plant material.

Animals

Adult male Wistar albino rats weighing 150–200 g were procured from Venkateshwara Enterprises, Bangalore, Karnataka, India and used throughout the study. All the animals were under the age of 8–12 weeks. They were housed in a very clean polypropylene cage and maintained under standard laboratory conditions (temperature 25 ± 2°C with dark/light cycle 12/12 h). They were fed with standard pellet diet and water *ad libitum*. The animals were acclimatized to laboratory conditions for one week before experiment. Experiments were performed complied with the rulings of the Committee for the Purpose of Control and Supervision of Experiments on Animals (CPCSEA) New Delhi, India under the registration No: 1135/a/07/CPCSEA.

Acute toxicity

Acute toxicity studies were performed as per OECD-423 guidelines [12]. Male Wistar albino rats selected by random sampling technique were utilized during this study. The animals were fasted for 4h with free access to water only. The plant extract was administered orally at a dose of 5mg/kg initially and mortality if any was observed for 3 days. If mortality was ascertained in two out of three animals, then the dose administered was considered as toxic dose. However, if the mortality was ascertained in only one animal out of three animals then the identical dose was repeated again to confirm the toxic effect. If no mortality was ascertained, then higher (50,300 and 2000 mg/kg) doses of extract were utilized for further toxicity studies.

Hepatoprotective Activity

Rats were divided into seven groups ($n = 6$) receiving the following treatments

Group I: Normal group received the vehicle (normal saline, 2 ml/kg, p.o.).

Group II: Received acetaminophen (750 mg/kg, p.o.) at every 72 h for 10days.

Group III: Received silymarin 50 mg/kg, p.o for 10days and simultaneously administered acetaminophen 750 mg/kg body wt. every 72 h.

Group IV: Received Methanol extract of *G.odorata roxb* 200 mg/kg, p.o. for 10 days and simultaneously administered acetaminophen 750 mg/kg body wt. every 72h.

Group V: Received Methanol extract of *G.odorata roxb* 400 mg/kg, p.o. for 10 days and simultaneously administered acetaminophen 750 mg/kg body wt. every 72h.

At the end of experimental period, all the animals were sacrificed by cervical decapitation. Blood samples were collected, allowed to clot. Serum was separated by centrifuging at 2500 rpm for 15 min and analyzed for various biochemical parameters such as Aspartate Amino Transferase (AST), Alanine Amino Transferase (ALT) [13], Alkaline Phosphates (ALP) [14], γ -Glutamate Transpeptidase (GGTP) [15], total bilirubin [16] and total protein [17].

Assessment of liver function

The liver was removed, morphological changes were observed. A 10 % of liver homogenate was used for antioxidant studies such as Lipid Peroxidation (LPO) [18], Superoxide Dismutase (SOD) [19], Catalase [20], Glutathione Peroxidase (GPx) [21] and Glutathione-S- Transferase (GST) [22]. A portion of liver was fixed in 10 % formalin for histopathological studies.

Histopathological studies

After draining the blood, liver samples were excised, washed with normal saline and processed separately for histopathological observation. At first the materials were fixed in 10 % buffered neutral formalin for 48h and then with bovine solution for 6 h. Paraffin sections were taken at 5 mm thickness processed in alcohol-xylene series and was stained with alum hematoxylin and eosin. The sections were examined microscopically for histopathology changes.

Statistical analysis

The data were expressed as mean \pm standard error of mean (SEM). Statistical significance was analyzed by one-way analysis of variance (ANOVA) followed by Dunnett's *posthoc* test of significance using Graph Pad (Instat) software version 4.0. *P* values of < 0.05 were considered as statistically significant.

RESULTS

Preliminary phytochemical studies revealed the presence of alkaloids, steroids, saponins, triterpenes, flavonoids and polyphenolic compounds. For the acute toxicity studies, the extract treated animals were observed for mortality up to 72h. Based on the results the extract did not produce any mortality up to 2000 mg/ kg body weight. The effect of *G.odorata roxb* on serum marker enzymes is presented in Figure 1. The levels of serum AST, ALT, ALP, total bilirubin, were markedly elevated and that of protein decreased in acetaminophen treated animals, indicating liver damage. Administration of *G.odorata roxb* extract at the doses of 200 and 400 mg/kg remarkably prevented acetaminophen-induced hepatotoxicity in a dose dependent manner.

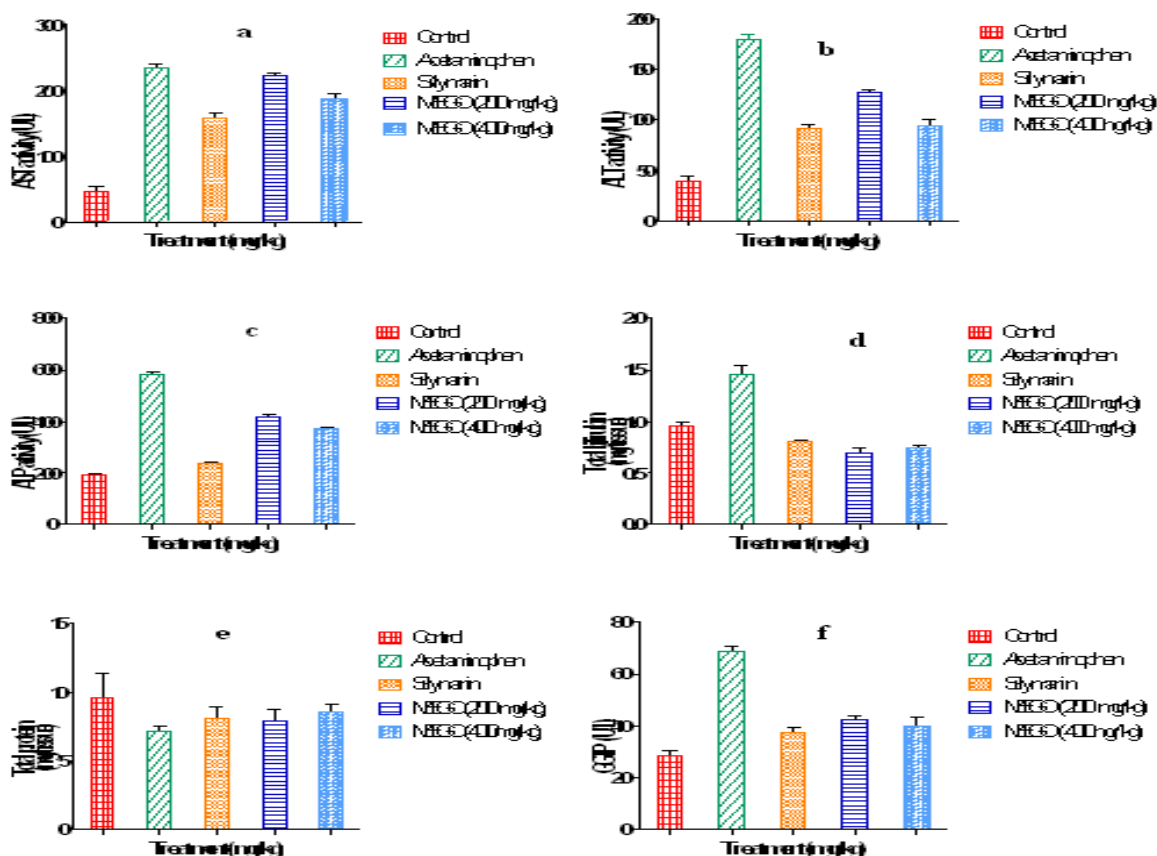


Figure 1: Hepatoprotective activity of methanol extract of *Gynocardia odorata* (MEGO)

(a) AST- Aspartate Amino Transferase, (b) ALT- Alanine Amino Transferase, (c) ALP- Alkaline Phosphatase, (d) Total bilirubin, (e) Total protein, (f) GGTP- Gamma Glutamate Transpeptidase and methanol extract of *Gynocardia odorata* (MEGO)

The localization of radical formation resulting in lipid peroxidation, measured as Malondialdehyde (MDA) contents in rat liver homogenate. MDA were increased in acetaminophen control group. MEGO 200 and 400 mg/kg were significantly inhibited MDA level in comparison to acetaminophen induced hepatic damage. The effect of *G.odorata roxb* was comparable with that of standard drug silymarin. Acetaminophen treatment caused a significant ($p < 0.001$) decrease in the level of SOD, catalase, GPx, and GST in liver tissue in comparison with normal group shown in Figure 2.

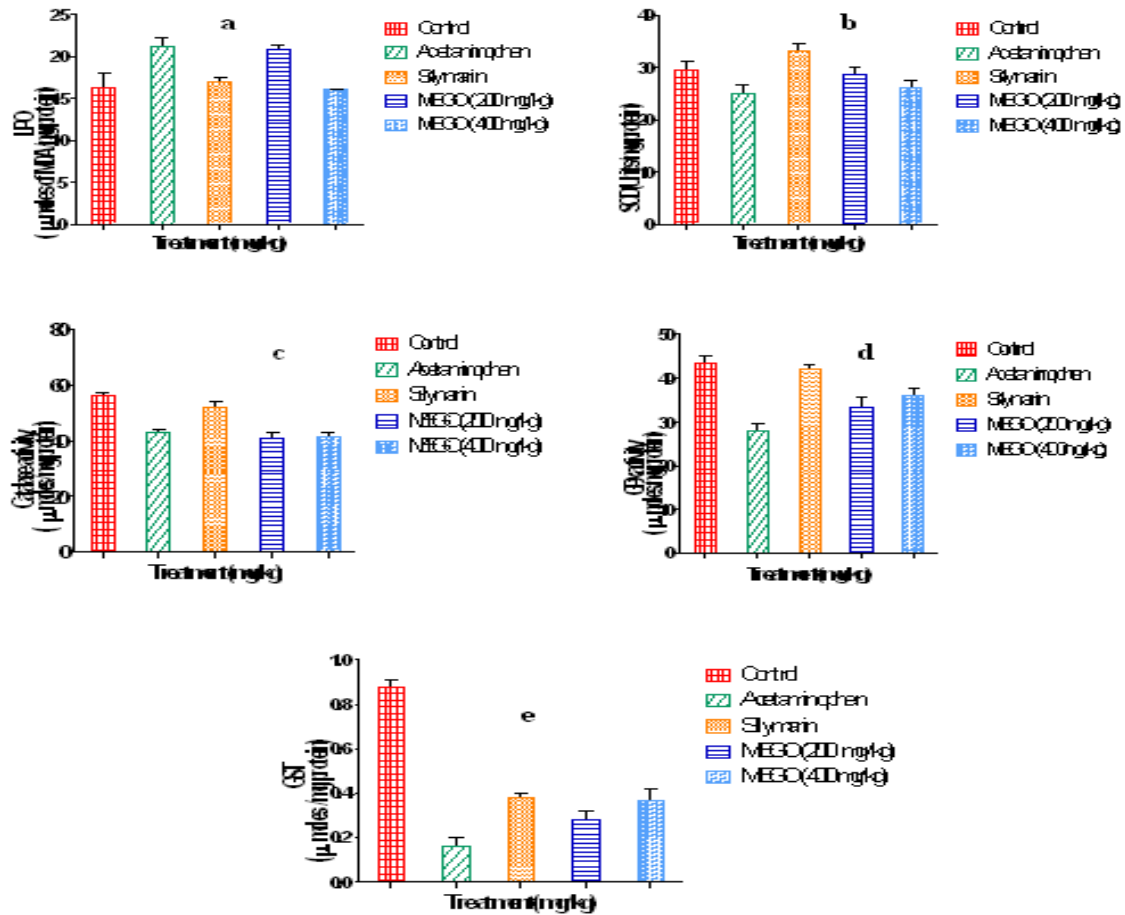


Figure 2: In-vivo antioxidant activity of methanol extract of *Gynocardia odorata* (MEGO)
 (a) LPO- Lipid Peroxidation, (b) SOD- Superoxide Dismutase, (c) CAT-Catalase, (d) GPx- Glutathione Peroxidase and (e) GST-Glutathione-S-Transferase and methanol extract of *Gynocardia odorata* (MEGO).

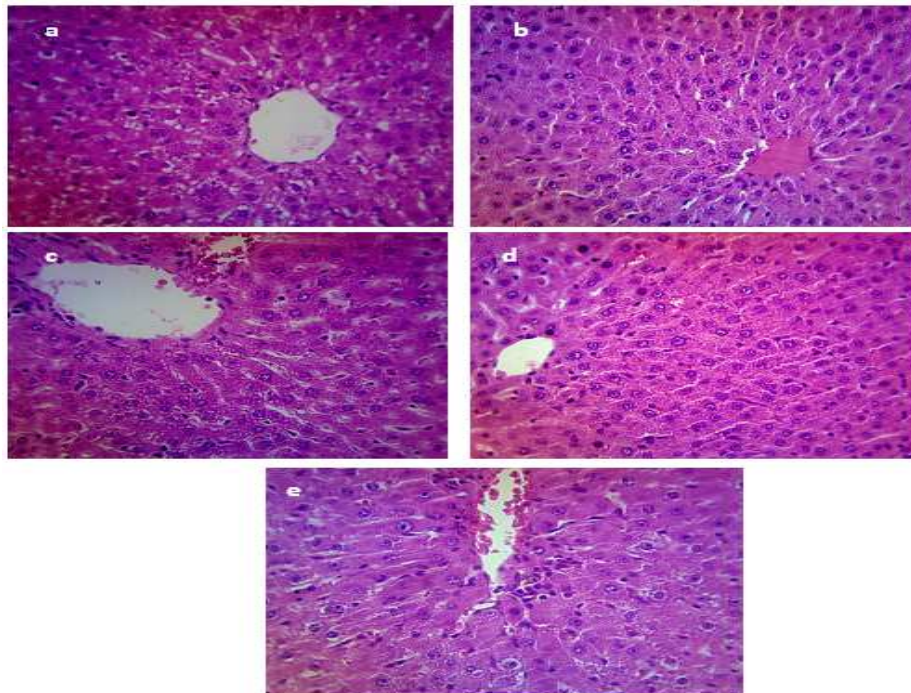


Figure 3: Histology slides showing hepatoprotective activity of methanol extract of *Gynocardia odorata* (MEGO) on liver cells

The treatment of *G. odorata roxb* at the doses of 200 and 400 mg/kg resulted in a significant increase of SOD, Catalase, GPx and GST in comparison to acetaminophen treated rats. The liver of silymarin treated animals also showed a significant increase in antioxidant enzymes levels compared to acetaminophen treated rats. Morphological observations showed an increased size and enlargement of the liver in acetaminophen treated groups. These changes were reversed by treatment with silymarin and also *G.odorata roxb* at the doses tested.

(a) Normal control treated rat: section showing normal hepatic cells. (b) Acetaminophen treated rat: section of liver showing fatty changes, increase inflammatory cell infiltrate and degenerative hepatocytes. (c) Rat treated with acetaminophen and 200 mg/kg body weight of MEGO shows fatty changes in hepatocytes and a few degenerated cells. (d) Rat treated with acetaminophen and 400 mg/kg body weight of MEGO shows normal hepatic cells. (e) Acetaminophen and 50 mg/kg body weight of silymarin treated rat shows normal hepatic cells.

Histopathological studies, showed acetaminophen to produced extensive vascular degenerative changes and centrilobular necrosis in hepatocytes. Treatment with different doses of *G.odorata roxb* extract produced mild degenerative changes and absence of centrilobular necrosis when compared with control (Figure 3). All these results indicate a hepatoprotective potential of the extract.

DISCUSSION

The present study documented the hepatoprotective activity for the methanolic extract of *G. odorata roxb* against liver injury induced by a toxic dose of acetaminophen. It is established that following an oral therapeutic dose, a fraction of acetaminophen is converted via the cytochrome p450 to a highly toxic metabolite, N-acetyl-p-benzoquinone-imine [23] (NAPQ1) which is normally conjugated with glutathione and excreted in the urine as conjugates. Overdose of acetaminophen deplete glutathionestores, leading to accumulation of NAPQ1, mitochondrial pathology [24] and the development of acute hepatic necrosis. Also depletion of glutathione enhances the expression of tumour necrosis alpha (TNF α). TNF α primes phagocytic NADPH oxidase to the enhanced production of oxygen free radicals and contributes to liver damage [25]. Studies demonstrated that acetaminophen induced hepatotoxicity can be modulated by substances that influence cytochrome P450 activity [26]. This is evidenced by an elevation in the serum marker enzymes namely AST, ALT, ALP, total bilirubin and decrease in protein.

In the assessment of liver injury by acetaminophen the determination of enzyme levels like AST, ALT is largely used. Necrosis or membrane damage releases the enzyme in to circulation and hence it can be measured in the serum. A high level of AST indicates liver injury, such as that caused by viral hepatitis as well as cardiac infarction and muscle injury.

AST catalyses the conversion of alanine to pyruvate and glutamate and is released in a similar manner. Therefore ALT is more specific to the liver, and is thus a better parameter for detecting liver injury. Elevated levels of serum enzymes are indicative of cellular leakage and loss of functional integrity of cell membrane in liver. Serum ALP, Bilirubin and total protein levels on other hand are related to the function of hepatic cell. Increase in serum level of ALP is due to increased synthesis, in presence of increasing biliary pressure [27]. Lipid peroxidation has been postulated to be the destructive process of liver damage due to acetaminophen intoxication [28]. GSH constitutes the first line defence against free radicals, as it is one of the abundant tripeptide non-enzymatic biological antioxidants present in the liver [29-30].

Administration of acetaminophen caused a significant ($p < 0.001$) elevation of enzyme levels such as AST, ALT, total bilirubin and decrease in total protein when compared to control. *G. odorata roxb* was significantly ($p < 0.001$) restored these biomarker enzyme levels in a dose dependent manner. The reversal of increased serum enzymes in acetaminophen induced liver damage by the extract may be due to the prevention of the leakage of intracellular enzymes by stabilizing structural integrity of the membrane or regeneration of damaged liver cells. The serum levels of transaminases return to normal with the healing of hepatic parenchyma and the regeneration of hepatocytes. Effective management of ALP, bilirubin and total protein levels points towards an early improvement in the secretory mechanism of the hepatic cells.

The increase in LPO level in liver induced by acetaminophen suggests increased lipid peroxidation resulting in tissue damage and failure of antioxidant defence mechanism to prevent formation of excessive free radicals. Treatment with *G.odorata roxb* significantly reverses these changes. Decrease in enzyme activity of superoxide dismutase (SOD) could be a sensitive index in hepatocellular damage and is the most sensitive enzymatic index in liver injury.

SOD has been reported as one of the most important enzymes in the enzymatic antioxidant defense system. It scavenges the superoxide anion to form hydrogen peroxide and thus diminishing the toxic effect caused by this radical. In *G.odorata roxb* causes a significant increase in hepatic SOD activity and therefore reduces reactive free radical induced oxidative damage to liver.

Catalase (CAT) is an enzymatic antioxidant widely distributed in all animal tissues, and also the highest activity is found in the red cells and liver. CAT decomposes hydrogen peroxide and protects the tissues from highly reactive hydroxyl radicals [31]. Thus reduction in the activity of CAT might result in a number of deleterious effects due to the assimilation of superoxide radical and hydrogen peroxide. A higher dose (400 mg/kg) will increase the level of CAT as created by silymarin, the standard hepatoprotective drug.

Glutathione is one among the most abundant tripeptide, non-enzymatic biological antioxidant present in the liver. It removes free radical species such as hydrogen peroxide, superoxide radicals and maintains membrane protein thiols. Also it is substrate for glutathione peroxidase (GPx) [32]. Decreased level of GSH is associated with an increased lipid peroxidation in acetaminophen treated rats. Administration of *G.odorata roxb* significantly ($p<0.001$) increased the level of GPx and GST in a dose dependent manner.

Extensive vascular degenerative changes and centrilobular necrosis in hepatocytes was produced by acetaminophen. Treatment with different doses of aerial parts of methanol extract of *G.odorata roxb* created only mild degenerative changes and absence of centrilobular necrosis, indicating its hepatoprotective potency.

Free radical mediated process has been implicated in pathogenesis of most of the diseases. The protective effect of *G.odorata roxb* on acetaminophen induced hepatotoxicity in rats seems to be related to inhibition of lipid peroxidation and enhancement of antioxidant enzyme levels in addition to free radicals scavenging action. Preliminary phytochemical studies reveal the presence of flavanoids in methanol extract of *G.odorata roxb*. Flavanoids were found to be good hepatoprotective agents [33].

CONCLUSION

The results of this investigation concluded that *G.odorata roxb* possesses good hepatoprotective activity with antioxidant effect and it may be due to the presence of flavanoids.. These attributes may provide the rationale for the use of *G. odorata roxb* in hepatotoxicity management by traditional healers. Further research is needed to fractionate the methanol extract and isolate the molecule(s) responsible for hepatoprotective activity observed.

REFERENCES

- [1] Girish C, Koner BC, Jayanthi S, Ramachandra Rao K and Rajesh B, *Fundam. Clin. Pharmacol.*, **2009**, 23, 735-745.
- [2] Aqil F, Ahmad I and Mehmood Z, *Turk. J. Biol.*, **2006**, 30, 177-183.
- [3] Salganik R I, *J. Am. Coll. Nutr.*, **2001**, 20, 464S-472S.
- [4] Yoshihara D, *Maturitas.*, **2010**, 67, 103-107.
- [5] Partap S and Pandey S, *J. Pharmacog. Phytochem.*, **2014**, 1, 26-37.
- [6] Roxburgh RW and Coromandel P. *Indian Council Med. Res.*, **1820**, 3(4), 95-299.
- [7] Jagan Mohan, Deepa L, Ubaidulla U and Ganesh N, *Int. J. Res. Pharm. Nano. Sci.*, **2013**, 2(3), 351 - 357.
- [8] Khan, Gupta N, Mohammed MS, Meetu A, Khan G and Mohan G, *Int. J. Dev. Res.*, **2013**, 3 (5), 49-54.
- [9] Shrish Kumar S, Hemant kumar and Mrityunjoy Acharya, *Am. J. Pharm. Tech. Res.*, **2014**, 4(1), 446-452.
- [10] Faisal A, Arshida ZB, Nur A, Muhammad T, Sharmin R C and Mohammad AR, *J. Anal. Sci. Tech.*, **2014**, 5, 36-38.
- [11] Harborne JB. *Phytochemical Methods: A Guide to Modern Techniques of Plant Analysis*. New Delhi: Springer (India) Pvt. Ltd. **1998**.
- [12] Ecobichon DJ. *The basis of Toxicology testing*. 1st Edn., CRC Press, New York, ISBN:10: 0849385547. **1997**.
- [13] Reitman S and Frankel A, *Am. J. Clin. Pathol.*, **1957**, 28, 56- 63.
- [14] Kind PR and King EJ, *J. Clin. Pathol.*, **1954**, 7, 322-326.
- [15] Szaszi G, *Clin. Chem.*, **1969**, 15, 124-136.
- [16] Malloy HT and Evelyn KA, *J. Biol. Chem.*, **1937**, 119, 481- 484.
- [17] Lowry OH, Rosenbrough NJ, Farr AL and Randall RJ, *J. Biol. Chem.*, **1951**, 193, 265-275.
- [18] Devasagayam TPA and Tarachand U, *Biochem. Biophys. Res. Commun.*, **1987**, 145, 134-138.
- [19] Marklund S and Marklund G, *Eur. J. Biochem.*, **1974**, 47, 469- 474.
- [20] Sinha AK, *Anal. Biochem.*, **1972**, 47, 389-394.
- [21] Rotruck JT, Pope A, Ganther HL and Swanson AB, *Science.*, **1973**, 179, 588- 590.

-
- [22] Habig WH, Pabst MJ and Jakoby WB, *J. Biol. Chem.*, **1974**, 249, 7130-7139.
- [23] Dahlin D, Miwa G and Lu A, *Proceedings of the National Acad Sci.*, **1984**, 81, 1327- 1331.
- [24] Parmar D, Ahmed G, Kandakumar MA and Katyare SS, *Eur. J. Pharmacol.*, **1995**, 293, 225- 229.
- [25] Gupta JW, Kubin M, Hartman L, Cassatella M and Trinchieri G, *Cancer. Res.*, **1992**, 52, 2530- 2537.
- [26] Mitchell JR, Jollow DJ, Potter WZ, Davis DC, Gillette JR and Brodie BB, *J. Pharmacol. Exp. Ther.*, **1973**, 187, 185- 194.
- [27] Muriel P, Garcipiana T, Perez-Advarez V and Mourelle M, *J. Appl. Toxicol.*, **1992**, 12, 439– 442.
- [28] Jeon GI, Yoon MY, Park HR, Lee SC and Park E, *Ann. New York Acad. Sci.*, **2009**, 1171, 576-582.
- [29] Erukainure OL, Ajiboye JA, Adejobi RO, Okafor OY and Adenekan SO, *Asian. Pac. J. Trop. Dis.*, **2011**, 1(1), 5-9.
- [30] Okafor OY, Erukainure OL, Ajiboye JA, Adejobi RO, Owolabi FO and Kosoko SB, *Asian. Pac. J. Trop. Biomed.*, **2011**, 1(1), 12-14.
- [31] Chance B, Greenstein DS and Roughton FJW, *Arch. Biochem. Biophys.*, **1952**, 37, 301– 321.
- [32] Prakash J, Gupta SK, Singh N, Kochupilla V, Gupta YK and Joshi S, *Phytother. Res.*, **2001**, 15, 240- 244.
- [33] Wegner T and Fintelmann V. *Wien. Med. Wochenschr.*, **1999**, 149, 241– 247.