



Scholars Research Library

Der Pharmacia Lettre, 2018, 11 [5] : 21-29
[<http://scholarsresearchlibrary.com/archive.html>]



Scholars Research
Library
ISSN 0975-5071
USA CODEN: DPLEB4

Protective Effect of *Centella asiatica* (L.) Urban on Heart and Kidney of Rat with Subtotal Nephrectomy

Nugrahaningsih DAA^{1,2}, Purnomo E³

¹Faculty of Medicine, Department of Pharmacology and Therapy, Public Health and Nursing, Universitas Gadjah Mada, Indonesia

²Faculty of Medicine, Center of Herbal Medicine, Public Health and Nursing, Universitas Gadjah Mad, Indonesia

³Faculty of Medicine, Department of surgery, Public Health and Nursing, Universitas Gadjah Mada, Indonesia

*Corresponding author: Nugrahaningsih DAA, Faculty of Medicine, Department of Pharmacology and Therapy, Public Health and Nursing, Universitas Gadjah Mada, Jalan farmako Sekip Utara Yogyakarta, Indonesia. Tel: +62(274)511103; Email: dwi.aris.a@ugm.ac.id

ABSTRACT

Background: *Centella asiatica* or pegagan is one of the widely use herbal in Indonesia. It's known for its therapeutics effect for many diseases, including Chronic Kidney Disease (CKD). However, lack of study to show its effect on CKD. Objective: The aim of the study is to investigate the protective effect of *Centella asiatica* on heart and kidney of CKD rats' model.

Methods: Twenty five rats were divided into 5 groups which were negative control group, captopril group, and 3 groups of *Centella asiatica* in 3 different doses. All rats were subtotal-nephrectomized and treated for 6 weeks. In the end of the treatment,

the blood pressure was measured and rats were sacrificed. The heart and kidney were collected for histological examination.

Result: *Centella asiatica* did not prevent the increase of blood pressure in CKD rat. However, the heart fibrosis, glomerulosclerosis and tubular injury score were lower in *Centella asiatica* group compare with those on negative control group.

Conclusion: Our study shows the potency of *Centella asiatica* as cardio-renal protective agent in CKD.

Keywords: *Centella asiatica* L., Urban, Kidney, Heart, Subtotal nephrectomy, Chronic Kidney Disease.

INTRODUCTION

Centella asiatica is valuable plants which have been used as traditional medicine for ages. People in many countries used to consume *Centella asiatica* in many ways such as eaten as raw vegetables, drink as juice, and many more for its health benefit. *Centella asiatica* contains various phytonutrient that provide wide range of health benefit. Its major chemical compounds are terpenoid compounds, asiaticoside, Asiatic acid, madecassic acid, asiaticoside, etc. [1]. *Centella asiatica* has the potency as antioxidant, antimicrobial, cytotoxic, neuro-protective, wound healing, anti-fibrotic, cardio-renal-protective and many other medicinal activities [2]. Preclinical and clinical studies have been done to prove the potency of *Centella asiatica* in various disease conditions such as atherosclerosis [3], diabetic wound [4], general anxiety disorder [5], and many other diseases. However, there are only a few scientific evidences that show the cardio-renal protective effect of *Centella asiatica* especially in Chronic Kidney Disease (CKD). The present study was designed to examine the protective effect of *Centella asiatica* on the heart and kidney of the rats with CKD induced by subtotal nephrectomy.

MATERIALS AND METHODS

Extraction process

Centella asiatica L. Urban was collected in Yogyakarta, Indonesia. The determination of the plant was done before the extraction process. The plant was washed, sun-dried and powdered. The powder was macerated in alcohol 70% for 24 hours. The maceration result was filtered and dried using freeze dryer.

Animal experiment

The whole experiment has been approved by ethic committee of Medical Faculty Universitas Gadjah Mada, Yogyakarta, Indonesia (ethical approval number is KE/FK/558/EC/2015). The animal model was developed on 12-14 weeks old male sprague dawley rat weighing 200-250 mg. The rats were kept in the animal facility of Medical Faculty Universitas Gadjah Mada where the temperature, humidity, light and airflow were tightly controlled. The rats also have free access to food and water. After subtotal nephrectomy procedure, they were randomized into 5 groups which are negative control group, captopril group (40 mg/kg body weight/day), *Centella asiatica* extract dose 1 group (126 mg/kg body weight/day), *Centella asiatica* extract dose 2 group (252 mg/kg body weight/day) and *Centella asiatica* extract dose 3 group (504 mg/kg body weight/day). Each group consists of 5 rats. The treatments were given orally. Six weeks after the treatment, the rat was sacrificed and their heart and kidney were harvested for further examination.

Subtotal nephrectomy

The sub-total nephrectomy procedure was performed in 2 stages. The first stage was removal of the superior and inferior pole of the right kidney. The second stage was removal of the whole left kidney. The second stage was done 1 week after the first stage operation to accommodate the healing of the kidney after the first stage operation. Before the nephrectomy procedure, rats were anesthetized using ketamine dose of 0.2 mg/kg BW.

Blood pressure

The blood pressure was measured one day before the rat scheduled to be sacrificed. We used CODA non-invasive blood pressure for rat (Kent Scientific Corp, USA) to measure their blood pressure. Briefly, the rat was acclimatized with the blood pressure equipment for 15 minutes before measuring the blood pressure. The blood pressure measurement was done at 08.00 am at quiet and separated space in the animal facility.

Histology

The heart and the kidney were preserved in normal buffer formaline (NBF) 10% for 24 hours before making the paraffine block. The organ block was sliced into 4 μ m. The heart section was stained using Hematoxylin Eosin (HE) staining. Meanwhile the kidney section was stained using Periodic Acid Schiff's (PAS) staining. The calculation of heart fibrosis, glomerular injury score and tubular injury score were done using previous published method [6,7].

Statistical analysis

All data are presented as the mean \pm SD. Statistical significance was determined using Kruskal-Wallis test followed by Dunn post hoc test to identify differences between the groups. Differences between groups were considered significant when $P < 0.05$. Analyses were performed using Graphpad Prism (Graph Pad Software, La Jolla, CA, USA).

RESULTS AND DISCUSSION

All off the rat were subtotal-nephrectomized before starting the treatment. The blood pressure measurement was done after 6 weeks of treatment. The blood pressures were high in all group except in captopril group. Figure 1 show the result of blood pressure measurement on week 6 of the treatment.

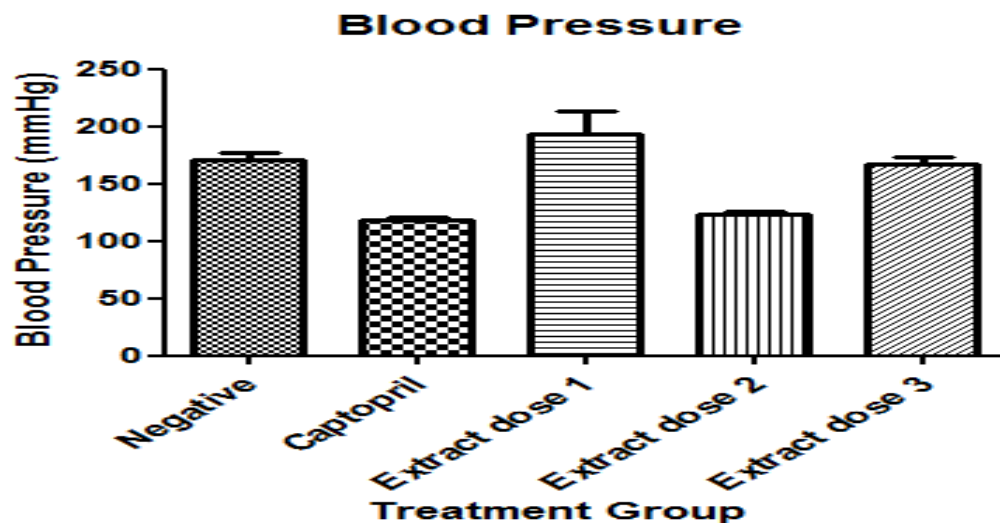


Figure 1: Result of blood pressure measurement using indirect non-invasive method after 6 weeks of treatment (n = 25).

Negative (negative control group, captopril (captopril group), extract dose 1 (*Centella asiatica* dose 1 group), extract dose 2 (*Centella asiatica* dose 2 group), extract dose 3 (*Centella asiatica* dose 3 group). * ($p < 0.05$ vs. negative control; Kruskal-Wallis test followed by Dunn post hoc test).

In our subtotal nephrectomy model, the rat blood pressure was increased until more than 160 mmHg. This result is similar with previous result of the other study using subtotal nephrectomy model [8], among the groups, captopril groups showed the lowest mean blood pressure value. Meanwhile, *Centella asiatica* groups did not show any different on mean blood pressure value

compare with those on negative control group. Previous study of *Centella asiatica* effect on venous hypertension microangiopathy patient shows that *centella asiatica* could improve the sign and symptom of the disease [9]. Meanwhile study on pulmonary hypertensive rat model showed the ability of asiaticoside, one of *Centella asiatica* active compound, to prevent the development of pulmonary hypertension induced by hypoxia. This activity was suggested due to its ability to enhance nitric oxide related signaling [10]. However, less is known about *Centella asiatica* activity on arterial hypertension. We also examined perivascular fibrosis on the heart tissue. We found that the perivascular fibrosis were more severe in the negative control group compare with those on captopril, extract dose 2 and extract dose 3 group. Figure 2 show the perivascular fibrosis score on the heart samples after 6 weeks of treatment.

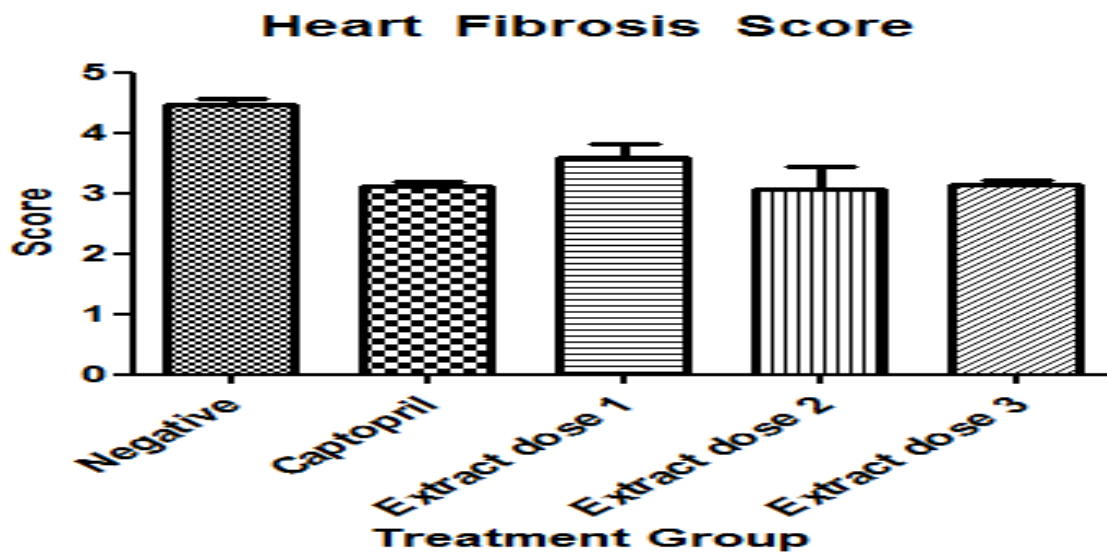


Figure 2: Perivascular fibrosis score on heart after 6 weeks of treatment (n= 25). Negative (negative control group, captopril (captopril group), extract dose 1 (*Centella asiatica* dose 1 group), extract dose 2 (*Centella asiatica* dose 2 group), extract dose 3 (*Centella asiatica* dose 3 group). * (p<0.05 vs negative control; Kruskal-Wallis test followed by Dunn post hoc test).

The result showed that both captopril and *Centella asiatica* extract dose 2 and dose 3 groups have lower perivascular fibrosis score on heart compare to those on negative control group. The treatment effect on the kidney showed on Figure 3 and Figure 4.

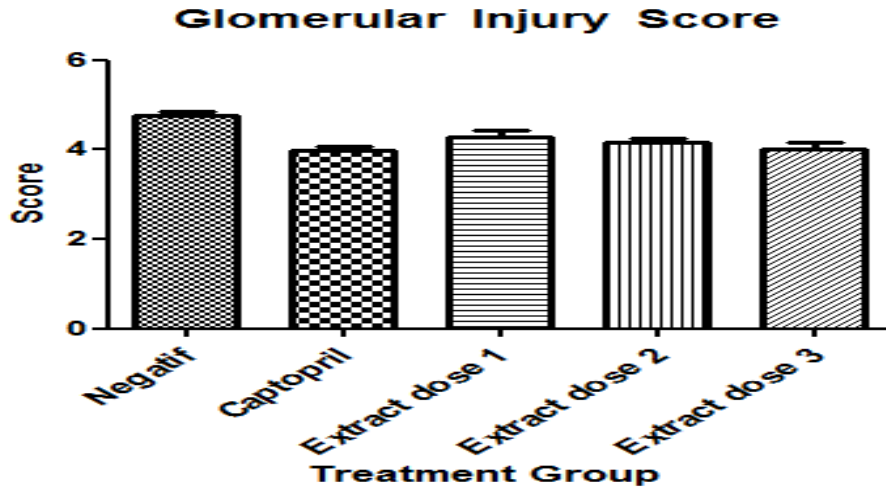


Figure 3: Glomerulosclerosis score after 6 weeks of treatment (n=25). Negative (negative control group, captopril (captopril group), extract dose 1 (*Centella asiatica* dose 1 group), extract dose 2 (*Centella asiatica* dose 2 group), extract dose 3 (*Centella asiatica* dose 3 group). *(p<0.05 vs negative control; Kruskal-Wallis test followed by Dunn post hoc test).

Glomerulosclerosis score result showed that both Captopril and *Centella asiatica* extract dose 3 group have lower score compare to those on negative control group.

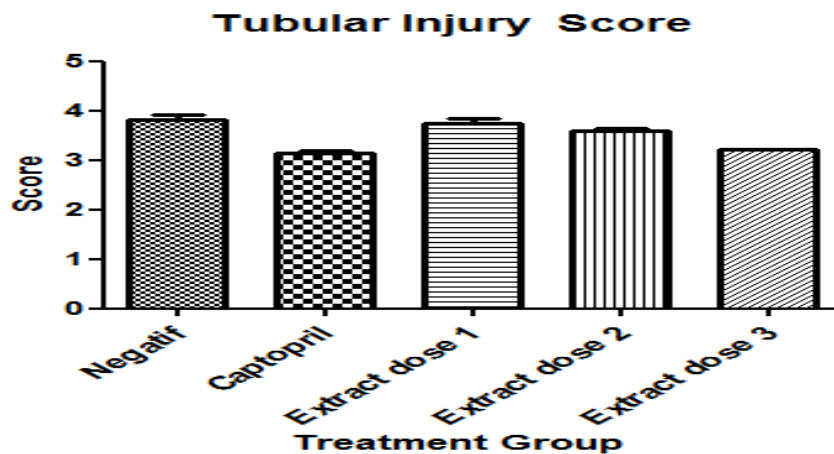


Figure 4: Tubular injury score after 6 weeks of treatment (n=25). Negative (negative control group, captopril (captopril group), extract dose 1 (*Centella asiatica* dose 1 group), extract dose 2 (*Centella asiatica* dose 2 group), extract dose 3 (*Centella asiatica* dose 3 group). *(p<0.05 vs. negative control; Kruskal-Wallis test followed by Dunn post hoc test).

Tubular injury score was lower in Captopril and *Centella asiatica* groups compare to those on negative control group. Our study showed the effect of *Centella asiatica* extract on the development of heart and kidney injury on subtotal nephrectomy model. Subtotal nephrectomy is an established model for chronic kidney disease (CKD) and it recently been used for assessing cardiorenal syndrome [11]. In this model, the reduction of kidney by removing 5/6 of the kidney is similar with the condition of CKD where the function of the kidney is greatly reduced. Therefore, only few nephrons left to carry out the whole kidney function. By the time, the remaining kidney will deteriorate due to overwork that later on result in the decrease of kidney function and will lead to CKD. Based on the previous study, after 6 weeks, the remaining kidney will show injury on both glomerular and tubular area. The cardiorenal symptom will also appear which is shown by injury on heart such as heart fibrosis [12].

In our study, the development of injury on heart and kidney also appear 6 week after subtotal nephrectomy procedure. They were shown by the increase of heart and kidney injury scar on negative control group heart and kidney histological samples examination as shown in previous figures. Our study showed that *Centella asiatica* treatment could prevent the development of kidney and heart injury in CKD rat model. However, *Centella asiatica* could not prevent the development of hypertension in subtotal nephrectomy model. We suggest that the cardio-renal protection mechanism is different between *Centella asiatica* and captopril. Captopril or other angiotensin converting enzyme inhibitor (ACEI) have been used to prevent the development of cardiovascular and renal damage on certain condition due to its effect on blood pressure and direct effect on organs [13,14]. However in our study, extract of *Centella asiatica* could prevent the development of kidney and heart injury in CKD rat model without preventing the increase of the blood pressure. Therefore we suggest that the mechanism of *Centella asiatica* extract on kidney and heart injury in this model is not related with blood pressure. Asiatic acid, one of the active compound of *Centella asiatica*, showed protective effect in myocardial infarct (MI) rat model which showed by inhibition of cardiac hypertrophy, reducing mRNA expression levels of inflammatory cytokines and decreasing interstitial fibrosis in the infarct border zone of MI model rats [15]. Meanwhile, in N^ω-nitro-L-arginine methyl ester hydrochloride (L-NAME)-induced hypertensive rats, Asiatic acid decrease blood pressure and prevents cardiac remodeling suggested due to its anti-inflammatory and antioxidant activity [16].

In contrast, our study showed that *Centella asiatica* extract administration could not prevent the blood pressure increase but prevent the cardiac fibrosis development. We suggest that it is due to the mechanism difference of hypertension and cardiac remodeling between subtotal-nephrectomy model and in L-NAME induced model. In our study the hypertension and cardiac remodeling is kidney related phenomena, meanwhile in L-NAME induced model, the blood pressure increase and cardiac remodeling is caused by inhibition of nitric oxide synthesise. *In vitro* study on normal renal mammalian fibroblast (NRK49F) and

tubular epithelial cells (NRK52E) showed that *Centella asiatica* have an antioxidant effect on NRK52E and apoptotic or anti-fibrotic effect on NRK49F which shows the potency of *Centella asiatica* as renoprotective agent [17]. Asiatic acid also found to be able to inhibit renal fibrosis in unilateral ureteral obstructive mice by blocking Smad3 and upregulating Smad7. [18,19]. Another study in adriamicyn induced nephropathy rat showed that *Centella asiatica* has the potency to act directly in the kidney to prevent the development of kidney injury [20].

CONCLUSION

In conclusion, our study has shown the cardio-renal protective effect of *Centella asiatica* extract in CKD rat model. It shows the potency of *Centella asiatica* as protective agent to prevent the development of heart and kidney remodeling in CKD.

REFERENCES

- [1]. Chandrika, UG., et al. Nutritional properties and plausible health benefits. *Adv. Food. Nutr. Res*, **2015**. 76:125-157.
- [2]. KJ. Gohil., et al. Pharmacological Review on *Centella asiatica*: A potential herbal cure-all. *Indian. J. Pharm. Sci*, **2010**. 72:546-556.
- [3]. Belcaro G., et al. Pycnogenol® and *centella asiatica* in the management of asymptomatic atherosclerosis progression. *Int. Angiol*, **2015**. 34:150-157.
- [4]. Paocharoen, V., The efficacy and side effects of oral *Centella asiatica* extract for wound healing promotion in diabetic wound patients. *J. Med. Assoc. Thai*, **2010**. 93(7): S166-S170.
- [5]. Jana, U., et al. A clinical study on the management of generalized anxiety disorder with *Centella asiatica*. *Nepal. Med. Coll. J*, **2010**. 12:8-11.
- [6]. Ye, VZ., et al. Early myocardial fibrosis is associated with depletion of vasoactive intestinal peptide in rat heart. *Exp. Physiol*, **2002**. 87:539-546.
- [7]. Garcia-Gomez, I., et al. Activated omentum slows progression of CKD. *J. AM. Soc. Nephrol*, **2014**. 25:1270-1281.
- [8]. Burrell, LM., et al. Chronic kidney disease: Cardiac and renal angiotensin-converting enzyme (ACE) 2 expression in rats after subtotal nephrectomy and the effect of ACE inhibition. *Exp. Physiol*. **2012**. 97:477-485.
- [9]. Incandela, L., et al. Total triterpenic fraction of *Centella asiatica* in the treatment of venous hypertension: A clinical, prospective, randomized trial using a combined microcirculatory model. *Angiology*, **2001**. 52(2):S61-67.
- [10]. Wang, X., et al. Effect of asiaticoside on endothelial cells in hypoxia-induced pulmonary hypertension. *Mol. Med. Rep*, **2018**. 17(2):2893-2900.

- [11]. Zhang, Y., Kompa, AR., A practical guide to subtotal nephrectomy in the rat with subsequent methodology for assessing renal and cardiac function. *Nephrology (Carlton)*, **2014**. 19(9):552-561.
- [12]. Yin, J., et al. Renalase attenuates hypertension, renal injury and cardiac remodelling in rats with subtotal nephrectomy. *J. Cell. Mol. Med*, **2016**. 20:1106-1117.
- [13]. Demers C., et al. Impact of candesartan on nonfatal myocardial infarction and cardiovascular death in patients with heart failure. *JAMA*, **2005**. 294:1794-1798.
- [14]. HH. Parving, et al. Long-term beneficial effect of ACE inhibition on diabetic nephropathy in normotensive type 1 diabetic patients. *Kidney. Int*, 2001. 60(1):228-234.
- [15]. Huo, L., et al. Asiatic acid inhibits left ventricular remodeling and improves cardiac function in a rat model of myocardial infarction. *Exp. Ther. Med*, **2016**. 11:57-64.
- [16]. Bunbupha, S., et al. Asiatic acid alleviates cardiovascular remodelling in rats with L-NAME-induced hypertension. *Clin. Exp. Pharmacol. Physiol*, **2015**. 42:1189-1197.
- [17]. Wojcikowski, K., et al. An *in vitro* investigation of herbs traditionally used for kidney and urinary system disorders: potential therapeutic and toxic effects. *Nephrology (Carlton)*, **2009**. 14:70-79.
- [18]. Meng XM., et al. Treatment of renal fibrosis by rebalancing TGF- β /Smad signaling with the combination of asiatic acid and naringenin. *Lan, Oncotarget*, **2015**. 6:36984-36997.
- [19]. Xu, C., et al. *Exp. Ther. Med*, **2013**. 6:731-736.
- [20]. Wang, Z., et al. Effects of asiaticoside on levels of podocyte cytoskeletal proteins and renal slit diaphragm proteins in adriamycin-induced rat nephropathy. *Life. Sci*, **2013**. 93:352-358.